

Case Report

Pregnancy-Associated Spontaneous Coronary Artery Dissection: Anesthetic Considerations

Alan M Iwahashi, Samantha H Garvanovic, Uoo R Kim, Melissa D McCabe *

Department of Anesthesiology, Loma Linda University Hospital, 11234 Anderson Street, MC2352, Loma Linda, CA 92354, USA; E-Mails: AlanIwahashi@llu.edu; SGarvanovic@llu.edu; URKim@llu.edu; MMcCabe@llu.edu

* **Correspondence:** Melissa D McCabe; E-Mail: MMcCabe@llu.edu

Academic Editor: Prashant Vaijyanath

Special Issue: [Orthotopic and Heterotopic Transplantation of the Heart](#)

OBM Transplantation

2025, volume 9, issue 1

doi:10.21926/obm.transplant.2501243

Received: August 29, 2024

Accepted: March 09, 2025

Published: March 20, 2025

Abstract

Spontaneous coronary artery dissection (SCAD) accounts for one-third of all peripartum myocardial infarction. Peripartum SCAD is associated with increased severity. We surmise that altered maternal cardiac physiology increases susceptibility to SCAD and warrants consideration when managing cardiac ischemia. One week after vaginal delivery, a 35-year-old woman with no known medical history developed multivessel SCAD and cardiogenic shock after attempted percutaneous coronary intervention, requiring rescue CABG and percutaneous VAD placement. She ultimately received an orthotopic heart transplant. SCAD disproportionately affects women, hormonal effects may contribute, however SCAD may herald occult arteriopathies. Pregnancy alters hemodynamics; cardiac output and circulating volume increase up to 150% at delivery. Most SCAD is successfully managed medically; procedural intervention is rare. Pharmacologic attenuation of the high-output state and procedural intervention may require consideration of fetal wellbeing. Pregnancy presents innate challenges for managing cardiac ischemia, especially in the presence of an undelivered fetus.



© 2025 by the author. This is an open access article distributed under the conditions of the [Creative Commons by Attribution License](#), which permits unrestricted use, distribution, and reproduction in any medium or format, provided the original work is correctly cited.

Keywords

Pregnancy; coronary artery dissection; case report

1. Introduction

Spontaneous coronary artery dissection (SCAD) is a nonatherosclerotic cause of acute coronary syndrome. The association between SCAD and pregnancy is increasingly recognized; pregnancy-associated SCAD (P-SCAD) tends to present with more proximal dissection, multivessel dissections, and systolic dysfunction. Nevertheless, few patients are referred for coronary artery bypass grafting (CABG). We present a case of postpartum SCAD requiring surgical management, including heart transplantation.

2. Case Report

Five days after an uncomplicated vaginal delivery with epidural analgesia, an otherwise healthy 35-year-old (gravida 2, para 2) woman presented with chest pain and was found to have a non-ST elevation myocardial infarction (MI) with deep T-wave inversions, acute systolic dysfunction with left ventricular ejection fraction (LVEF) 45-50%, severe mitral regurgitation, and pulmonary edema requiring mechanical ventilation. Coronary angiography was initially read as unremarkable. Dual antiplatelet therapy and metoprolol were initiated with improvement in symptoms. She was discharged on hospital day 5 but returned the following day with worsening chest pain and rising troponin levels. ECG was significant for diffuse precordial ST depressions and transient elevation in leads V1-V3. Repeat angiography demonstrated dissections in the left main (30%, ostium to distal), 40% first diagonal, 40% proximal left circumflex, and 30% first obtuse marginal coronary arteries (Figure 1). Given ongoing ischemia and acute heart failure despite medical therapy, dissection propagation was suspected. A multidisciplinary team (interventional cardiology, cardiac surgery) deemed the LM dissection to be unstable, thus warranting intervention. Intravascular ultrasound was used to identify the true lumen in anticipation of complex percutaneous coronary intervention (PCI); however, engagement of the circumflex artery resulted in lateral wall ischemia and hemodynamic instability. A percutaneous ventricular assist device (PVAD, Impella CP, ABIOMED® Danvers, MA) was placed and mechanical ventilatory support was initiated. PCI was reattempted unsuccessfully and urgent rescue three-vessel CABG surgery was performed (left internal mammary-left anterior descending, saphenous vein graft-obtuse marginal, saphenous vein graft-diagonal). Despite true-to-false lumen vessel tacking, coronary dissections extended distal to all bypass anastomoses and no intraluminal thrombi were seen. Due to persistent hemodynamic instability, she was transferred to our center for refractory cardiogenic shock and transplant evaluation. Admission chest x-ray was notable for an enlarged cardiac silhouette (Figure 2). Evacuation of hemothorax and hemopericardium and PVAD upgrade (Impella 5.5, ABIOMED® Danvers, MA) were performed, and she was listed United Network for Organ Sharing status 2e for orthotopic heart transplantation. After multiple unsuccessful attempts to wean PVAD support, she underwent orthotopic heart transplantation. With pre-induction arterial pressure transduction, Impella set at P5, and a Norepinephrine infusion at 3 µg/min, a stable plane of general endotracheal

anesthesia was induced with 1% Isoflurane, intravenous Midazolam 2 mg, Fentanyl 200 µg, Lidocaine 100 mg, Etomidate 10 mg, Rocuronium 100 mg, Epinephrine 10 µg, and Phenylephrine 100 µg. A transesophageal echocardiography probe and right internal jugular pulmonary artery catheter were placed. Recipient cardiectomy was completed with 2 minutes of circulatory arrest and retrograde cerebral perfusion. The new heart was transplanted in bicaval fashion and she separated from bypass on inotropic infusions (Epinephrine 5 µg/min, Norepinephrine 2 µg/min, vasopressin 0.04 units/min, Dobutamine 5 µg/kg/min). Extensive hemostasis was performed, followed by closure and transport to the cardiac intensive care unit. Postoperative left ventricular systolic function was normal and right ventricular systolic function was mildly decreased. She was eventually weaned off all cardiac support, and more than fifty days postpartum was ambulatory with New York Heart Association class I-II functional status and LVEF of 60-65% (Table 1).

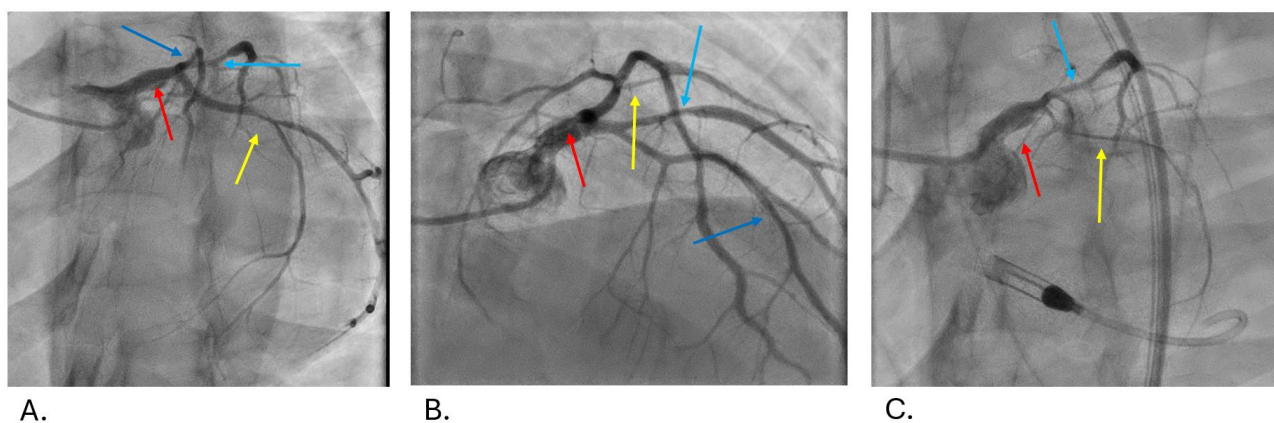


Figure 1 Coronary Angiography. A. Left anterior oblique caudal view, a dissection flap is seen within the left main coronary artery (red arrow). Narrowing is seen in the left anterior descending (dark blue arrow), mid-left circumflex (yellow arrow), as well as the first diagonal coronary (light blue arrow). B. Anteroposterior cranial view, redemonstrating the dissection flap within the left main coronary artery (red arrow). Narrowing is also seen within the left circumflex (yellow arrow) and first diagonal coronaries (light blue arrow). The dark blue arrow shows the left anterior descending coronary. C. Angiography demonstrating severe global reduction in coronary blood flow within the left circumflex (yellow arrow) and the diagonal (light blue arrow). Flow within the left anterior descending coronary artery is notably absent. Interval placement of a percutaneous ventricular assist device.

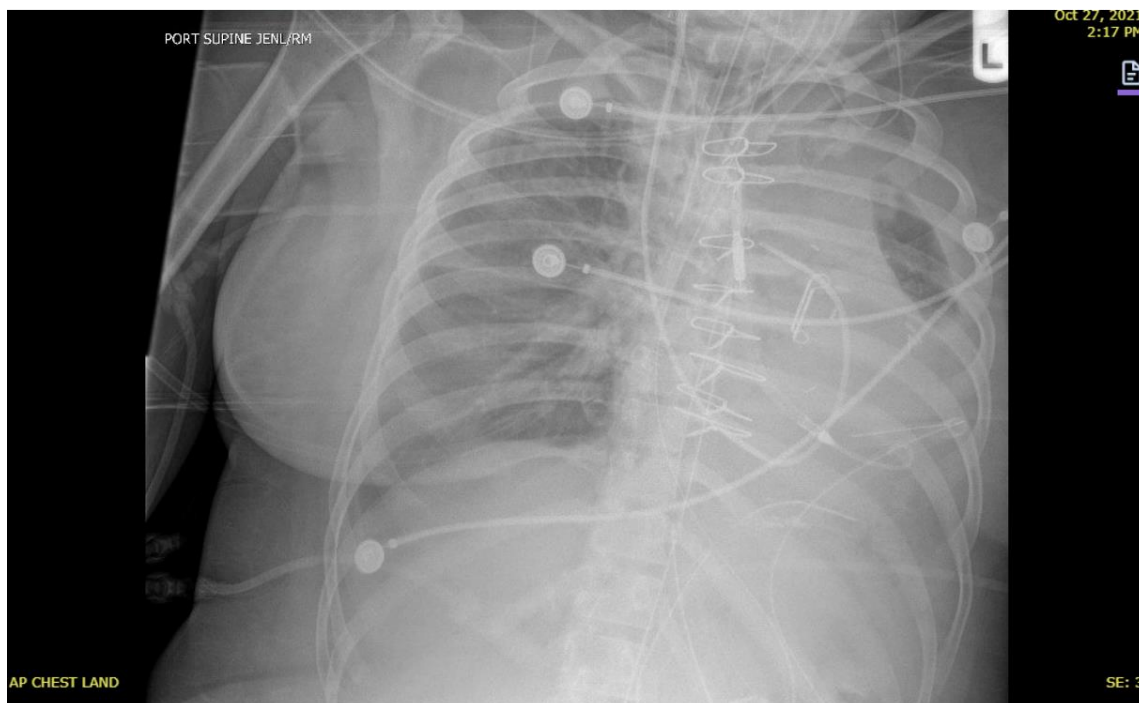

Figure 2 Admission chest x-ray. Chest x-ray demonstrating mediastinal widening, enlarged cardiac silhouette, and blunting of the left costophrenic angle prior to evacuation of hemo-pericardium and hemothorax.

Table 1 Event Timeline.

Day	Description of Events
0	Admission for routine term delivery
1	Epidural (Ropivacaine 0.2% 5 ml, Fentanyl 2 µg/ml, Bupivacaine 0.125%), uncomplicated delivery
3	Discharge
5	Non-ST elevation myocardial infarction (troponin >100 pg/ml with hypotension, acute MR, systolic dysfunction (LVEF 45%), pulmonary edema requiring intubation). No culprit lesion identified on coronary angiography.
9	Improving MR, angina, troponin (18 pg/m), discharged with aspirin 81 mg, clopidogrel 75 mg, metoprolol succinate 25 mg
10	Returned with persistent angina, transient ST segment elevation (V1-V3), repeat angiography showing multivessel SCAD, including LMCA. Impella (ABIOMED® Danvers, MA) 3.5-assisted PCI attempt unsuccessful, followed by rescue CABG (LIMA-LAD, SVG-OM, SVG-diagonal, LAA closure, Impella repositioning).
12	Transfer to LVAD/ECMO/transplant capable center; Impella upgraded to axillary 5.5, evacuation of hemo-pericardium, hemothorax (Figure 2).
25	Ventricular tachycardia, improved with Impella repositioning, lidocaine infusion
26	Initial heart transplant attempt, cancelled due to poor graft fit
28	Ambulatory with Impella set at P2, dobutamine at 2 µg/kg/min; LVEF 30%
44	Successful orthotopic heart transplant; axillary Impella removed, neurologically intact on arrival from operating room.

48 Extubated with inhaled nitric oxide weaned to 5 parts per million

56 Discharged, ambulatory, neurologically intact, off all hemodynamic support

ECMO: extracorporeal membrane oxygenation; LVAD: left ventricular assist device; LVEF: left ventricular ejection fraction; LAA: left atrial appendage; LIMA: left internal mammary artery; MR: mitral valve regurgitation; NSTEMI: non-ST segment elevation myocardial infarction; OM: obtuse marginal artery; SCAD: spontaneous coronary artery dissection; SVG: saphenous vein graft.

3. Discussion

SCAD occurs when a nontraumatic intramural hemorrhage causes partial to complete coronary luminal occlusion. The predominance of SCAD among women and the association with oral contraceptives suggest hormonal influences on vessel wall structure, which may potentially be magnified during pregnancy [1]. Connective tissue disease and inflammatory disorders have also been postulated as risk factors [2]. P-SCAD affects about 1.8/100,000 pregnancies [3] and is estimated to account for more than one-third of peripartum myocardial infarctions [4]. Socioeconomically, young white women of the highest income quintile appear to be most affected [5] with an average presenting age of 35 ± 4 years [6]. P-SCAD is associated with higher rates of proximal dissection, multivessel dissections, systolic dysfunction (LVEF $\leq 35\%$) and transmural MI [6]. Examination of SCAD using cardiac computed tomography (CCT) found a significantly shorter left main (LM) coronary length, increased left anterior descending (LAD) coronary tortuosity and angle of the adjacent arterial branch in SCAD compared with healthy subjects [7]. These anatomic features may accentuate local vascular shear stress. The increased disease severity observed in pregnancy warrants consideration of underlying maternal cardiovascular physiology, which includes a high cardiac output state (Figure 3).

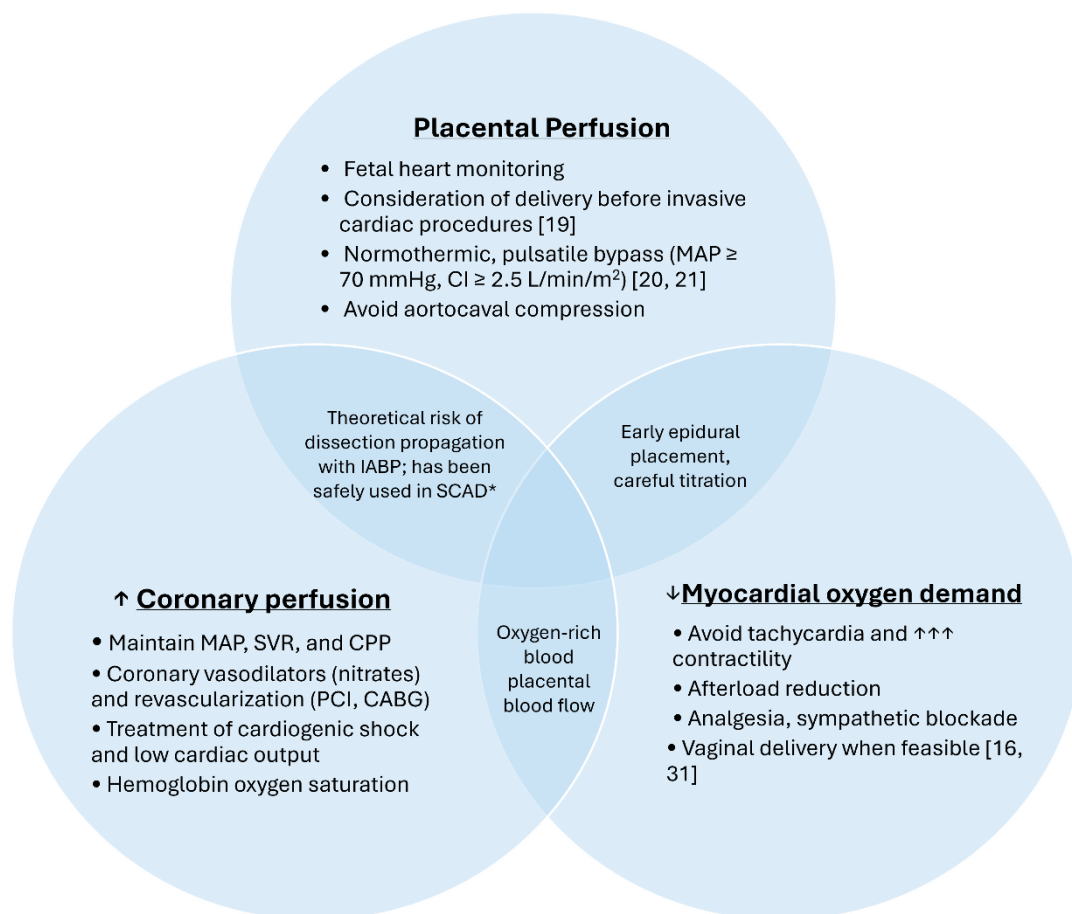


Figure 3 Hemodynamic management in pregnancy-related spontaneous coronary artery dissection (SCAD). The goals for hemodynamic management of pregnancy-related SCAD should balance maternal myocardial oxygen demand and coronary perfusion while continuing to support placental perfusion. CABG: coronary artery bypass grafting; CI: cardiac index; CPP: coronary perfusion pressure; IABP: intra-aortic balloon counter pulsation; MAP: mean arterial pressure; PCI: percutaneous coronary intervention; SVR: systemic vascular resistance* [8].

P-SCAD presents with new-onset chest pain in >90% of parturients late in the third trimester or early postpartum period [9]. Significantly higher rates of ST elevation myocardial infarction (STEMI), left main, multivessel coronary involvement, and resultant reduction in LVEF have been observed in P-SCAD than in cases unrelated to pregnancy [10]. The proportion of patients with LVEF <35% has also been reported as significantly higher in P-SCAD (26% vs 10%) [6] and represents a subgroup for which early intervention may be more heavily considered. Notably, the presenting LVEF in our case report (45-50%) was likely overestimated due to the presence of severe mitral regurgitation. In a subset of patients presenting with P-SCAD and STEMI, left main disease was significantly higher than in non-pregnant patients and was almost uniformly associated with significant long-term reduction in LVEF [11]. Mortality is rare in pregnancy-related SCAD and is most frequently due to fatal arrhythmia [12]. Nevertheless, most SCAD even when associated with reduced LVEF, responds favorably to medical therapy alone [13, 14].

SCAD is typically diagnosed with conventional coronary angiography, however advanced intraluminal imaging such as intravascular ultrasound and optical coherence tomography may help

provide confirmation in diagnostically challenging cases and facilitate identification of the true lumen prior to PCI. Angiography confers significant risk of dissection extension and non-invasive medical management alone is preferred whenever possible.

Medical management of P-SCAD mirrors therapy for acute atherosclerotic MI with the following additional considerations: 1) beta blockers may be used in pregnancy after carefully weighing the risk of fetal growth restriction, 2) systemic heparin is stopped upon diagnosis of SCAD given its mechanism, 3) statins are contraindicated in pregnancy and lactation, and have been associated with an increased risk of SCAD recurrence [15]. Low-dose aspirin (81 mg) is acceptable after 12 weeks gestational age and is used as prophylaxis against severe preeclampsia [16]. Nitroglycerin promotes both coronary vasodilation and uterine relaxation, of which the latter may be undesirable during delivery.

Hemodynamic management is a mainstay of anesthetic care; most P-SCAD presents after delivery, allowing for sole consideration of maternal physiology. When P-SCAD presents prior to delivery, care should be given to balancing myocardial oxygen supply and demand with antianginal therapy, while maintaining adequate systemic vascular resistance and uterine perfusion pressure, given that placental blood flow is not autoregulated. Early epidural placement confers the benefit of controlling sympathetic tone (directly by sympathectomy) and indirectly through analgesia but may require expert consultation on the management of antiplatelet therapy. Vaginal delivery is associated with fewer acute hemodynamic changes than Cesarean delivery. Similarly, titrated induction of epidural anesthesia may be preferred over intrathecal to minimize acute drops in systemic vascular resistance [17].

Interventional management of P-SCAD is typically reserved for refractory angina, progressive hemodynamic or electrical instability despite maximal medical therapy. Acute systolic dysfunction often underlies hemodynamic instability and is associated with higher mortality [18]. Although low cardiac output may require inotropic support, the use of mechanical support (MCS) and heart transplantation in P-SCAD remains rare. In a series of particularly severe P-SCAD (N = 120, 75% rate of STEMI), a total of 5 patients ultimately required mechanical support or heart transplant [10].

PCI and CABG both contend with the technical difficulty of delicate, unstable coronary dissections during revascularization. Lesions involving critical anatomy (left main or proximal left anterior descending) or multivessel SCAD are particularly high risk. Despite a high technical failure rate, PCI often is the first-line intervention for SCAD [19], while CABG may be considered as first-line therapy for unstable critical left main or proximal left anterior descending and multivessel dissections [20]. The fraction of P-SCAD treated by CABG surgery has been shown to be significantly higher than in SCAD unrelated to pregnancy, often as front-line therapy [6]. Postoperatively, the need for good long-term medical management remains, as the durability of bypass conduits may gradually be threatened by competitive native arterial flow once spontaneous healing occurs [15].

The intraoperative anesthetic approach and hemodynamic monitoring for P-SCAD undergoing cardiac surgery is like that in non-pregnant patients, however, as outlined above the hemodynamic goals must balance myocardial oxygen demand and coronary perfusion with placental blood flow. Cardiopulmonary bypass during pregnancy notably confers a particularly high risk of fetal compromise, with estimates of 20-30% and potentially >50% in the setting of New York Heart Association class IV heart failure [21]. Fetal morbidity and mortality are also increased when cardiac surgery is performed at an earlier gestational age [22]. If the fetus is viable, Cesarean delivery prior to CABG has been successfully performed and may significantly reduce fetal mortality [23]. This is

not a trivial decision, requiring multidisciplinary collaboration as the patient's hemorrhage risk may be influenced by reduced uterine tone due to coronary vasodilators, and high dose heparinization for cardiopulmonary bypass. If delivery closely precedes cardiac surgery, neuraxial anesthesia may be precluded by the risk of neuraxial hematoma in the setting of anticipated systemic anticoagulation [24].

When delivery prior to cardiac surgery is undesirable, modifications to cardiopulmonary bypass including maintaining cardiac index $>2.5-3.5$ L/min/m², mean arterial pressure >70 mmHg, pulsatile flow, and normothermia may offer protection for the mother and fetus [21, 22]. Off-pump CABG techniques avoid fetal exposure to the inflammatory and hypothermic effects of the bypass circuit but requires appropriate patient selection, a decision beyond the scope of this discussion. Fetal heart tone and uterine pressure monitoring may be considered to assess adequacy of placental perfusion during procedural intervention; however, it is important to note that monitoring may not always be feasible.

As P-SCAD is increasingly recognized, anesthesiologists may encounter formerly affected patients presenting for non-cardiac surgical and obstetrical care. For timing of elective noncardiac surgery, the updated 2024 American College of Cardiology-American Heart Association guidelines for preoperative cardiovascular management maintain a recommendation of 12 months without interruption of dual antiplatelet therapy for those with prior PCI for acute coronary syndrome and makes a strong recommendation for a multidisciplinary approach to preoperative cardiovascular decision-making [25]. The previous edition also contains data suggesting ≥ 60 days period between medically-managed MI and elective noncardiac surgery [26]. Most SCAD patients are treated noninvasively and while interval angiography has demonstrated spontaneous vessel healing in as little as 2-3 months [27], dissection persistence has been observed at 6 months in medically managed SCAD [28]. Furthermore, SCAD recurrence is unpredictable with an incidence ranging from 4.7 to 10.4%, and often involves new lesions [29]. Beta blockers and blood pressure control may reduce recurrence risk, yet this remains to be prospectively validated [30]. A substantial fraction of SCAD patients report a preceding physical or emotional stressor [2] and SCAD is associated with higher rates of post-event anxiety and depression, than atherosclerotic acute MI [31].

Conceiving after SCAD is generally discouraged [32] and if future pregnancies are desired, multidisciplinary coordination with obstetricians, cardiologists, and anesthesiologists is prudent to assess the risks and coordinate delivery planning. Early epidural placement and planned delivery allow for some control of the physiological stress of labor and delivery. Despite preventive measures, anesthesiologists may ultimately be tasked with the initial management of SCAD-related cardiac ischemia, underscoring the importance of understanding the entire the disease process within the framework of maternal cardiac physiology and fetal demands.

Glossary of Terms

SCAD	spontaneous coronary artery dissection
P-SCAD	pregnancy associated spontaneous coronary artery dissection
CABG	coronary artery bypass grafting
MI	myocardial infarction
PCI	percutaneous coronary intervention
LVEF	left ventricular ejection fraction

pVAD percutaneous ventricular assist device

Author Contributions

Alan M Iwahashi: assisted with data acquisition and helped draft and edit the manuscript. He approves of the final approval of the version to be published and agrees to be accountable for all aspects of the work in ensuring that questions related to the accuracy or integrity of any part of the work are appropriately investigated and resolved. **Samantha H Garvanovic:** helped draft and edit the manuscript. She approves of the final approval of the version to be published and agrees to be accountable for all aspects of the work in ensuring that questions related to the accuracy or integrity of any part of the work are appropriately investigated and resolved. **Uoo R Kim:** cared for the patient, assisted with conceptualization, and helped edit the manuscript. He approves of the final approval of the version to be published and agrees to be accountable for all aspects of the work in ensuring that questions related to the accuracy or integrity of any part of the work are appropriately investigated and resolved. **Melissa D McCabe:** cared for the patient, assisted with conceptualization and data acquisition, helped draft and edit the manuscript and figures. She approves of the final approval of the version to be published and agrees to be accountable for all aspects of the work in ensuring that questions related to the accuracy or integrity of any part of the work are appropriately investigated and resolved.

Competing Interests

The authors have declared that no competing interests exist.

References

1. Tweet MS, Miller VM, Hayes SN. The evidence on estrogen, progesterone, and spontaneous coronary artery dissection. *JAMA Cardiol.* 2019; 4: 403-404.
2. Saw J, Aymong E, Sedlak T, Buller CE, Starovoytov A, Ricci D, et al. Spontaneous coronary artery dissection: Association with predisposing arteriopathies and precipitating stressors and cardiovascular outcomes. *Circ Cardiovasc Interv.* 2014; 7: 645-655.
3. Faden MS, Bottega N, Benjamin A, Brown RN. A nationwide evaluation of spontaneous coronary artery dissection in pregnancy and the puerperium. *Heart.* 2016; 102: 1974-1979.
4. Tweet MS, Lewey J, Smilowitz NR, Rose CH, Best PJ. Pregnancy-associated myocardial infarction: Prevalence, causes, and interventional management. *Circ Cardiovasc Interv.* 2020; 13: e008687.
5. Mughal MS, Akbar H, Kaur IP, Ghani AR, Mirza H, Xia W, et al. Contemporary trends in the incidence of spontaneous coronary artery dissection (SCAD)-ethnic and household income disparities. *Expert Rev Cardiovasc Ther.* 2022; 20: 485-489.
6. Tweet MS, Hayes SN, Codsì E, Gulati R, Rose CH, Best PJ. Spontaneous coronary artery dissection associated with pregnancy. *J Am Coll Cardiol.* 2017; 70: 426-435.
7. Di Donna C, Cavallo AU, Pugliese L, Ricci F, De Stasio V, Presicce M, et al. Anatomic features in SCAD assessed by CCT: A propensity score matching case control study. *Ann Cardiol Angeiol.* 2021; 70: 161-167.

8. Yang C, Inohara T, Alfadhel M, McAlister C, Starovoytov A, Choi D, et al. Spontaneous coronary artery dissection and cardiogenic shock: Incidence, etiology, management, and outcomes. *J Am Coll Cardiol*. 2021; 77: 1592-1594.
9. Campbell KH, Tweet MS. Coronary disease in pregnancy: Myocardial infarction and spontaneous coronary artery dissection. *Clin Obstet Gynecol*. 2020; 63: 852-867.
10. Havakuk O, Goland S, Mehra A, Elkayam U. Pregnancy and the risk of spontaneous coronary artery dissection: An analysis of 120 contemporary cases. *Circ Cardiovasc Interv*. 2017; 10: e004941.
11. Lobo AS, Cantu SM, Sharkey SW, Grey EZ, Storey K, Witt D, et al. Revascularization in patients with spontaneous coronary artery dissection and ST-segment elevation myocardial infarction. *J Am Coll Cardiol*. 2019; 74: 1290-1300.
12. Chan N, Premawardhana D, Al-Hussaini A, Wood A, Bountziouka V, Kotecha D, et al. Pregnancy and spontaneous coronary artery dissection: Lessons from survivors and nonsurvivors. *Circulation*. 2022; 146: 69-72.
13. Franco C, Starovoytov A, Heydari M, Mancini GJ, Aymong E, Saw J. Changes in left ventricular function after spontaneous coronary artery dissection. *Clin Cardiol*. 2017; 40: 149-154.
14. Krittanawong C, Nazir S, Virk HH, Hahn J, Wang Z, Fogg SE, et al. Long-term outcomes comparing medical therapy versus revascularization for spontaneous coronary artery dissection. *Am J Med*. 2021; 134: e403-e408.
15. Naderi S. Spontaneous coronary artery dissection and pregnancy. *Curr Treat Options Cardiovasc Med*. 2017; 19: 69.
16. American College of Obstetricians and Gynecologists. ACOG committee opinion No. 743: Low-dose aspirin use during pregnancy. *Obstet Gynecol*. 2018; 132: e44-e52.
17. Lau ES, Aggarwal NR, Briller JE, Crousillat DR, Economy KE, Harrington CM, et al. Recommendations for the management of high-risk cardiac delivery: ACC cardiovascular disease in women committee panel. *JACC Adv*. 2024; 3: 100901.
18. Díez-Villanueva P, García-Guimarães M, Sanz-Ruiz R, Sabaté M, Macaya F, Roura G, et al. Prognostic implications of left ventricular systolic dysfunction in patients with spontaneous coronary artery dissection. *Eur Heart J Acute Cardiovasc Care*. 2023; 12: 299-305.
19. Tweet MS, Eleid MF, Best PJ, Lennon RJ, Lerman A, Rihal CS, et al. Spontaneous coronary artery dissection: Revascularization versus conservative therapy. *Circ Cardiovasc Interv*. 2014; 7: 777-786.
20. Krittanawong C, Gulati R, Eitzman D, Jneid H. Revascularization in patients with spontaneous coronary artery dissection: Where are we now? *J Am Heart Assoc*. 2021; 10: e018551.
21. Shook LL, Barth WHJ. Cardiac surgery during pregnancy. *Clin Obstet Gynecol*. 2020; 63: 429-446.
22. Elassy SM, Elmidany AA, Elbawab HY. Urgent cardiac surgery during pregnancy: A continuous challenge. *Ann Thorac Surg*. 2014; 97: 1624-1629.
23. van Steenberg GJ, Tsang QH, van der Heijden OW, Vart P, Rodwell L, Roos-Hesselink JW, et al. Timing of cardiac surgery during pregnancy: A patient-level meta-analysis. *Eur Heart J*. 2022; 43: 2801-2811.
24. Horlocker TT, Vandermeulen E, Kopp SL, Gogarten W, Leffert LR, Benzon HT. Regional anesthesia in the patient receiving antithrombotic or thrombolytic therapy: American society of regional anesthesia and pain medicine evidence-based guidelines (fourth edition). *Reg Anesth Pain Med*. 2018; 43: 263-309.

25. Thompson A, Fleischmann KE, Smilowitz NR, de Las Fuentes L, Mukherjee D, Aggarwal NR, et al. 2024 AHA/ACC/ACS/ASNC/HRS/SCA/SCCT/SCMR/SVM guideline for perioperative cardiovascular management for noncardiac surgery: A report of the American College of Cardiology/American Heart Association joint committee on clinical practice guidelines. *Circulation*. 2024; 150: e351-e442.
26. Fleisher LA, Fleischmann KE, Auerbach AD, Barnason SA, Beckman JA, Bozkurt B, et al. 2014 ACC/AHA guideline on perioperative cardiovascular evaluation and management of patients undergoing noncardiac surgery: A report of the American College of Cardiology/American Heart Association Task Force on practice guidelines. *Circulation*. 2014; 130: e278-e333.
27. Saw J. Coronary angiogram classification of spontaneous coronary artery dissection. *Catheter Cardiovasc Interv*. 2014; 84: 1115-1122.
28. Rogowski S, Maeder MT, Weilenmann D, Haager PK, Ammann P, Rohner F, et al. Spontaneous coronary artery dissection: Angiographic follow-up and long-term clinical outcome in a predominantly medically treated population. *Catheter Cardiovasc Interv*. 2017; 89: 59-68.
29. Adlam D, Alfonso F, Maas A, Vrints C. European society of cardiology, acute cardiovascular care association, SCAD study group: A position paper on spontaneous coronary artery dissection. *Eur Heart J*. 2018; 39: 3353-3368.
30. Saw J, Humphries K, Aymong E, Sedlak T, Prakash R, Starovoytov A, et al. Spontaneous coronary artery dissection: Clinical outcomes and risk of recurrence. *J Am Coll Cardiol*. 2017; 70: 1148-1158.
31. Murphy BM, Rogerson MC, Hesselson S, Iismaa SE, Hoover V, Le Grande M, et al. Prevalence of anxiety, depression, and distress in SCAD and non-SCAD AMI patients: A comparative study. *J Cardiopulm Rehabil Prev*. 2023; 43: 338-345.
32. Tweet MS, Hayes SN, Grimaldo AB, Rose CH. Pregnancy after spontaneous coronary artery dissection: Counseling patients who intend future pregnancy. *JACC Adv*. 2023; 2: 100714.