

Review

Tuberculosis Screening and Treatment in Solid Organ Transplantation

David J. Epstein ^{1,*}, Aruna K. Subramanian ²

1. Division of Infectious Diseases and Geographic Medicine, Department of Medicine, Stanford University, 300 Pasteur Drive, Lane building, Mail code 5107, Stanford, CA 94305, United States; E-Mail: depstein@stanford.edu
2. Division of Infectious Diseases and Geographic Medicine, Department of Medicine, Stanford University, 300 Pasteur Drive, Lane building, Mail code 5107, Stanford, CA 94305, United States; E-Mail: asubram2@stanford.edu

* **Correspondence:** David J. Epstein; E-Mail: depstein@stanford.edu

Academic Editor: Maricar Malinis

Special Issue: [Diagnosis and Management of Infections in Solid Organ Transplant Recipients](#)

OBM Transplantation

2019, volume 3, issue 1

doi:10.21926/obm.transplant.1901048

Received: November 18, 2018

Accepted: January 28, 2019

Published: February 12, 2019

Abstract

Background: Tuberculosis (TB) is a common infection with challenges in diagnosis and treatment. Management of TB in solid organ transplant (SOT) candidates and recipients poses unique challenges not seen in other populations.

Questions and Recommendations: Latent TB infection (LTBI) is important to diagnose pre-transplant through history, physical examination, imaging, and laboratory tests. Tuberculin skin tests and interferon-gamma release assays are important tools but not sufficiently sensitive nor specific to diagnose LTBI alone. Active TB is more likely to present as a disseminated or extrapulmonary infection in SOT recipients. Donor-derived infections occur infrequently though can be serious; these can sometimes be prevented through LTBI treatment of the donor or recipient. Treatment of active or latent TB is similar to that in other populations with particular attention to drug interactions and adverse drug reactions.



© 2019 by the author. This is an open access article distributed under the conditions of the [Creative Commons by Attribution License](#), which permits unrestricted use, distribution, and reproduction in any medium or format, provided the original work is correctly cited.

Conclusions: LTBI and TB are important infections in SOT candidates and recipients with unique challenges though substantial literature and experience have emerged to guide providers.

Keywords

Solid organ transplantation; tuberculosis; latent tuberculosis infection; opportunistic infections; donor derived infections

1. Introduction

Tuberculosis (TB) is an endemic infection with significant morbidity and mortality if not properly treated. Diagnosis and treatment of TB is complex, particularly in solid organ transplant (SOT) candidates or recipients. Identification and treatment of individuals with latent TB infection (LTBI) is an important strategy in prevention of TB disease, but is further complicated in the context of SOT.

TB most often occurs in SOT recipients through reactivation of latent infection in the context of immunosuppression. Occasionally, patients with unrecognized active, but perhaps subclinical TB undergo transplantation followed by clinical worsening such that TB is later diagnosed. Another mechanism of infection, particularly in countries of high TB endemicity, involves de novo infection after transplant due to contact with an active TB case. Finally, donor-derived infection occurs though is likely uncommon.

SOT recipients are at a significantly increased risk of TB relative to comparator groups, occurring at over four times the rate of the general population and in some older studies occurring at nearly 100-times the rate of comparator populations [1-5]. This increased incidence persists even when comparing SOT recipients to patients with end-organ disease not undergoing transplantation [6]. Incidence rates vary widely in different studies depending on study country, population characteristics, transplanted organ, and protocols (if any) for diagnosing and treating LTBI. Among SOT recipients, lung transplant recipients seem to have the highest risk for post-transplant TB [7].

2. Questions and Recommendations

2.1 Evaluation and Treatment of LTBI

2.1.1 How Should Providers Screen SOT Candidates or Recipients for LTBI?

Providers should preferentially screen SOT candidates for LTBI before transplantation. In fact, some patients undergoing evaluation for transplantation may already be at increased risk of TB reactivation. Patients with end-stage renal disease, diabetes mellitus, and silicosis, for example, benefit from screening for and treatment of LTBI based on these indications alone regardless of transplant candidacy [8]. Moreover, some patients being evaluated for transplantation are on immunosuppressive medications, including corticosteroids, that confer an increased risk of TB reactivation and warrant LTBI screening and treatment [8].

Screening for LTBI in SOT candidates involves obtaining a history of prior TB infection and disease. In patients with an established history of LTBI or active TB, providers should seek records of prior treatment when available. In such patients, commonly used tests for LTBI such as the tuberculin skin test (TST) and interferon-gamma release assay (IGRA) are not valid since they cannot distinguish prior from current infection. Assuming documentation or reliable patient history confirms adequate prior treatment for LTBI or active TB, there is generally no role for re-treatment except in circumstances conferring a very high risk for reactivation, for example, contact with a known smear-positive TB case. As with any other patient, these patients should be evaluated clinically and radiographically for evidence of active TB prior to transplant. The management of patients with self-reported histories of treatment for latent or active TB without documentation should be individualized. These patients may require serial imaging and collection of sputum for culture to rule out active disease.

All potential transplant candidates without a known prior history of TB or LTBI should undergo screening with a TST or IGRA, either an enzyme-linked immunosorbent assay or enzyme-linked immunospot. These tests generally have only fair or moderate concordance, but any positive test should likely be considered evidence of LTBI [9-16]. In fact, for patients with high risk of LTBI based on epidemiologic exposures and a negative MTB IGRA, a TST may be a useful test to detect LTBI. An indeterminate result obtained from an IGRA, which typically reflects failure of the patient's lymphocytes to respond sufficiently to a mitogen due to impaired cellular immunity, can sometimes be resolved by repeating the test. Both the TST and MTB IGRA predict risk of TB post-transplant, though IGRAs may be more sensitive than TSTs in SOT candidates and demonstrate greater specificity among those previously vaccinated with the *Bacillus Calmette-Guérin* vaccine [2, 17-19]. Still, sensitivity of both tests is poor in many populations awaiting transplant, perhaps under 50% in those on hemodialysis [17].

In all patients, regardless of TST or IGRA results, a single-view or two-view chest X-ray (CXR) should be obtained unless a recent study is available to assess for evidence of active TB or LTBI. This imaging is also important for detecting other occult infections requiring evaluation and treatment prior to transplantation. Signs or symptoms potentially consistent with active TB should be elicited, such as a cough for more than two or three weeks, fever, sweats, weight loss, dyspnea, or chest pain. Patients with imaging, signs, or symptoms potentially consistent with active pulmonary TB should undergo sputum examinations or invasive workup such as bronchoscopy to evaluate for active TB or other infectious processes. Those with unexplained back, bone, or joint pain or swelling; lymphadenopathy; meningitis; pericardial or pleural effusions; or ascites should be evaluated for extrapulmonary TB.

2.1.2 How Should SOT Candidates or Recipients with A Positive Test for LTBI Be Further Evaluated?

As with all patients, those with a positive TST or IGRA should be examined with a CXR to assess for evidence of active TB. A computed tomography (CT) scan should be considered to characterize CXR abnormalities. Any CXR or CT findings potentially consistent with active TB—including fibrotic lesions or other infiltrates, non-calcified nodules, cavities, adenopathy, or pleural effusions—should prompt collection of sputum for acid-fast bacilli (AFB) smear and culture and TB nucleic acid amplification testing. Fully calcified lymph nodes or nodules alone are not consistent with active TB and do not by themselves require sputum culture. Otherwise, radiographic features

alone cannot reliably distinguish active from latent TB so any of these abnormalities should prompt sputum examination. While bronchoscopy can be pursued, and may be useful in evaluating other causes of airspace opacities, bronchoalveolar lavage is no more sensitive than induced sputum culture for the diagnosis of pulmonary TB [20, 21].

Since imaging, particularly CXRs, can occasionally be normal in patients with active TB, especially in immunocompromised patients, induced or expectorated sputum should be obtained for any patient with signs or symptoms potentially consistent with TB, such as cough for two weeks or more, weight loss, fevers, or night sweats. Moreover, laryngeal TB may result in a chronic cough with normal findings on chest CT scans.

2.1.3 Should SOT Candidates or Recipients with A Negative Test for LTBI Be Further Evaluated for Possible Infection?

In SOT candidates with a high pre-test probability of LTBI, such as those from endemic countries or with prior TB contact, chest CT should be considered (to detect evidence of prior TB infection such as calcified granulomas) even with negative TST or IGRA results and normal CXR findings [22]. Prior CT or chest CXR studies should be reviewed for radiographic features consistent with prior TB infection. In fact, patients with CXR findings suggestive of prior TB (fibrosis or calcified nodules) or CT findings of prior TB (calcified or non-calcified nodules, fibrosis, or irregular linear opacities) were more likely to develop TB in one study of liver transplant candidates regardless of TST or IGRA results [23].

2.1.4 What Medication Regimens Should Be Used for Treatment of LTBI in SOT Candidates or Recipients and When Should Treatment Be Initiated?

Nine months of isoniazid (9H) has traditionally been the mainstay of LTBI therapy due to its established efficacy and relative safety [24]. Isoniazid has established benefit in prevention of TB reactivation in SOT recipients [25]. Isoniazid has few significant drug-drug interactions (DDIs), is widely available, and is generally safe, though the regimen is long with occasional development of clinically significant hepatotoxicity. To mitigate the risk of peripheral neuropathy, pyridoxine should be given with isoniazid in this patient population given the frequency of comorbidities which increase the likelihood of this complication [24]. Based on case reports of failures of pyridoxine to prevent isoniazid-associated neuropathy in patients on dialysis, some authors have suggested very high dose pyridoxine in these patients [26].

Rifampin-based regimens have also been used for LTBI treatment, and early studies have demonstrated similar efficacy with shorter durations of therapy [27]. A large multinational randomized control trial recently found that 4 months of rifampin (4R) was not inferior to 9H in prevention of active TB among patients with LTBI and associated with a better safety profile and higher completion rates [28]. Critically, however, rifampin has many significant DDIs that complicate its use in SOT candidates and recipients. Rifampin is a potent inducer of proteins involved in drug metabolism, including cytochrome P450 (CYP) proteins, enzymes involved in glucuronidation, and membrane transporters like P-glycoprotein [29, 30]. Through these pharmacokinetic effects, rifampin significantly reduces the effects of calcineurin inhibitors (CNIs), and to a lesser degree mycophenolate and corticosteroids [31]. Rifampin's effects on drug metabolism can persist for up to 4 weeks after drug discontinuation so this agent should not be

used for the treatment of LTBI in SOT recipients or SOT candidates who may undergo transplantation in the near future [32]. To account for both brief interruptions of therapy that sometimes occur and to allow normalization of pharmacokinetic parameters, providers should probably only start 4R if transplant will not occur in the next 6 months. Rifampin's effects on drug metabolism may preclude its use in patients on a variety of other important medications before or after SOT.

Rifabutin is a rifamycin with an identical mechanism of action to rifampin that can be used in place of rifampin for treatment of LTBI [24]. Relative to rifampin, rifabutin has less profound effects on drug metabolism, though it will still lower CNI levels, for example. Disadvantages of rifabutin relative to rifampin include potentially higher cost, unique but uncommon adverse drug reactions (ADRs) including uveitis, and bidirectional drug interactions such that certain CYP inhibitors will increase rifabutin levels [24]. Still, rifabutin may be a useful agent to treat LTBI in patients who may not tolerate isoniazid but for whom rifampin is contraindicated due to DDIs [33].

A combination of weekly rifapentine and isoniazid for 12 weeks (3HP) is also as effective as 9H and, like 4R, and is associated with higher rates of treatment completion [34]. While initially recommended only in the context of directly observed therapy, 3HP has subsequently been found to be efficacious as self-administered therapy and recommendations now permit both treatment administration options [35, 36]. While hepatotoxicity is less common with 3HP compared to 9H, more patients on 3HP had to permanently discontinue the regimen due to ADRs [34]. Moreover, 3HP is associated with a "flu-like syndrome" consisting of fevers, chills, myalgias, and headache, constituting over two-thirds of the systemic drug reactions in 3HP patients [37]. Finally, rifapentine is associated with similar DDIs that characterize rifampin.

Overall, we generally favor either 9H or 4R, though 3HP and 4 months of rifabutin are advantageous options in select patients. When no concerns for rifamycin DDIs exist (including knowing that SOT will not occur for six months), many treatment choices exist and the regimen should be selected based on patient and provider preferences and individual patient circumstances. Patients with an increased risk for isoniazid-associated hepatotoxicity by virtue of advanced age, concomitant hepatotoxic medications, or other factors, should generally be treated with 4R given a lower incidence of drug-induced liver injury (DILI). The 9H regimen is generally preferred in SOT recipients or SOT candidates who may undergo transplantation in the near future. In select patients who are unable to tolerate 9H or who have particular risk factors for hepatotoxicity, in whom rifampin would normally be considered but for whom the drug is contraindicated due to DDIs or impending transplantation, 4 months of rifabutin can be used, understanding DDIs still occur.

While LTBI treatment can often be started immediately, sometimes delaying treatment is prudent. In patients with cough or abnormal chest imaging, LTBI treatments should be withheld until active TB can be fully excluded to avoid development of drug resistance through the unintentional treatment of active TB with only one or two drugs. Even if transplant is imminent, there is usually no urgency in proceeding with LTBI therapy. In fact, the median time to clinical presentation of TB after SOT is 22.5 or 17.5 months based on cohort studies and case series, respectively [38]. Among the nearly 2,000 SOT recipients in cohort studies who developed TB, the earliest case of TB occurred 2.4 months after transplant [38]. This delayed development of TB in SOT patients, in contrast to the rapid reactivation after a median of 12 weeks in those treated with

infliximab, allows transplant providers the confidence to delay treatment until it can be done optimally.

2.1.5 Can Patients with Cirrhosis or Acute Liver Failure Be Treated for LTBI?

Given the potential hepatotoxicity of medications used for the treatment of LTBI, liver transplant candidates with LTBI can be particularly challenging. Some liver transplant candidates, namely those whose indication for transplant is hepatocellular carcinoma, may have preserved synthetic function and minimal fibrosis and may tolerate LTBI treatment as well as other SOT candidates. Many others, however, have cirrhosis or acute liver failure. Given the potentially devastating consequences that DILI could have on those with decompensated cirrhosis or acute liver failure, LTBI treatment in these patients should generally be deferred until after liver transplant when the liver function stabilizes: many providers wait one to two months post-transplant to start LTBI therapy. Similarly, LTBI therapy is sometimes best deferred in patients with compensated cirrhosis but with significantly abnormal baseline liver tests (for example alanine transaminase values of greater than 3 times the upper limit of normal or bilirubin values greater than 2 mg/dL).

Patients with compensated cirrhosis can often be safely treated for LTBI pre-transplant. As discussed above, 4R is a particularly attractive regimen in these patients, assuming transplantation will not occur in the next 6 months and no other significant drug interactions preclude its use. Otherwise, 9H can often be safely used with close monitoring [39-41]. Rifabutin for 4 months can also be used with the caveat that DDIs still do occur [33].

Levofloxacin and moxifloxacin are active against MTB and have been attractive candidate drugs for LTBI treatment in liver-transplant candidates or recipients given lower rates of hepatotoxicity than isoniazid and significantly fewer DDIs than rifampin. Fluoroquinolone-based regimens have been used for LTBI treatment among contacts with multi-drug resistant TB, though evidence for efficacy is sparse relative to the standard LTBI treatment regimens [42, 43]. A promising multi-center study comparing levofloxacin versus isoniazid in liver-transplant candidates and recipients was stopped early due to a high incidence of sometimes-severe tenosynovitis though a small case series also reported infrequent ADRs with a fluoroquinolone-based regimen [44, 45]. Still, because efficacy and safety have not been sufficiently demonstrated relative to 9H, 4R (or 4 months of rifabutin), or 3HP, fluoroquinolone-based regimens cannot be routinely recommended.

2.2 Prevention of Donor Derived Infection

2.2.1 Can TB Be Transmitted through SOT?

Over 30 cases of donor-derived TB have been reported [38, 46]. Viable TB bacilli from transplanted organs, lymphatic tissue or other structures associated with transplanted organs, or presumably uncommonly in blood are likely sources of donor-derived TB. While lung transplant recipients accounted for more cases than other SOT recipient groups, kidney, heart, and liver SOT recipients have also developed donor-derived TB [38, 46]. Donor-derived TB often occurs early, with a median time to occurrence of approximately 3 months after SOT [38, 46].

2.2.2 Should Organ Donors Be Screened for LTBI?

Though no evidence is available to guide recommendations on prevention of donor-derived TB, a consensus conference report outlines a sensible approach [47]. These recommendations prioritize avoiding SOT in the context of a donor with active TB. To this end, providers should use history, physical examination, and CXR to evaluate for active TB among living and deceased donors. Bronchoscopy should be performed on lung donors for AFB cultures in case of unrecognized active TB. Among donors from TB-endemic countries, particularly in the context of kidney transplantation, urine studies (including urinalysis and AFB urine cultures) and genitourinary imaging should be considered to rule out genitourinary TB. Living donors should also generally be screened for LTBI with an MTB IGRA or TST; there is insufficient evidence to recommend routinely performing MTB IGRA or TST on deceased donors.

For deceased donors with a history of LTBI who were insufficiently treated, LTBI recipient should be considered for the recipient, particularly in the case of lung transplant. Living donors with a positive MTB IGRA or TST can undergo a full course of treatment before donation if time allows. Alternately, SOT can proceed and the recipient can be treated subsequently.

2.3 Diagnosis and Treatment of TB Disease

2.3.1 How Does Active TB Present after SOT and How Should Diagnosis Be Pursued?

Compared to immunocompetent patients with TB, SOT recipients with TB are more likely to present with extrapulmonary or disseminated disease (in nearly half of cases) [38]. Pulmonary TB occurred in over three-quarters of lung transplant patients with post-transplant TB [38]. While pulmonary TB was the most common manifestation of post-transplant TB in kidney transplant recipients, among patients with extrapulmonary TB, the urinary tract was a frequent site of involvement [38].

Radiographic findings in pulmonary TB can be subtle or non-specific; CXRs can be normal or can have lobar consolidations, interstitial infiltrates, or nodules [38, 48]. Cavitory disease occurs but is less common than other radiographic features; still, upper lobe disease predominates as with immunocompetent patients with pulmonary TB [38, 48, 49]. Patients with donor-derived TB sometimes present with organ-specific manifestations, for example allograft-related wound dehiscence or abscess due to TB [50, 51].

2.3.2 How Should Patients with Active TB after SOT Be Treated?

Treatment of SOT recipients with TB mostly follows general principles for treatment of TB [52]. Multidrug therapy is initiated pending antimicrobial susceptibility testing results; therapy is initiated empirically after specimens are obtained for culture when there is a high suspicion for active TB without waiting for culture confirmation. Still, some unique features of SOT recipients influence therapeutic considerations. Daily, rather than intermittent therapy, should likely be used as in the case of other immunocompromised patients [52]. Pyridoxine should be universally administered given the frequent multiple comorbidities of SOT recipients [52]. These patients should be evaluated at least monthly with blood counts and chemistries [52].

Drug interactions pose particular challenges in this population. As discussed previously, rifampin is associated with significant decreases in CNI effectiveness, and to a lesser extent the effectiveness of mycophenolate and corticosteroids. Still, given the critical role of rifamycins in treatment of TB and prolonged duration of treatment required when using rifamycin-sparing regimens (at least 12-18 months), regimens should almost always contain a rifamycin [52]. Rifabutin should generally be used in place of rifampin since rifabutin is a less potent inducer of drug metabolism, though its effects can still be pronounced. Rifamycins (particularly rifampin) also substantially induce metabolism of mold-active azoles frequently used for prophylaxis or treatment in the context of SOT [53, 54]. In patients for whom mold-active azole use is important, rifabutin should similarly be preferentially used. Isavuconazole should likely be avoided given lack of widely available therapeutic drug monitoring (TDM); posaconazole suspension and itraconazole are relatively poorly absorbed. Posaconazole tablets and voriconazole are more likely to attain therapeutic levels when co-administered with rifamycins. Unlike rifampin, there are bidirectional DDIs with rifabutin: mold-active azoles are CYP inhibitors which may increase rifabutin levels; rifabutin TDM may be indicated in these cases.

Renal and hepatic disease, not uncommon in SOT recipients, pose additional management challenges. Among first-line drugs, ethambutol and pyrazinamide require dose adjustment in the context of renal insufficiency [52]. Ethambutol can be particularly dangerous in the context of renal impairment given risk of optic neuropathy; TDM or replacing ethambutol with moxifloxacin or levofloxacin can be considered in these patients [52]. Patients with baseline liver disease should be monitored closely since DILI associated with TB medications could be devastating. In patients with severe baseline liver disease, some providers omit pyrazinamide, which requires extending total treatment to 9 months [52]. Another option for patients with severe baseline liver disease involves avoiding isoniazid and pyrazinamide by treating with rifampin, ethambutol, and levofloxacin or moxifloxacin though treatment is typically extended to 12 months [52]. Finally, for patients with severe, unstable liver disease who have no physiologic reserve for any DILI, a regimen with little or no potential for hepatotoxicity could be employed, such as ethambutol, levofloxacin or moxifloxacin, cycloserine, and an injectable agent with a total treatment duration of 18 months [52].

2.3.3 Can Patients with Active TB Undergo SOT?

Active TB has historically been considered a relative contraindication to SOT. Ideally, TB treatment would be completed before SOT to reduce the risk of worsening infection, DDIs, and ADRs associated with hepatotoxic or nephrotoxic medications. Still, SOT during treatment for active TB could be considered in selected patients, particularly among patients with drug-susceptible TB who are responding to TB therapy and when delaying SOT would be dangerous. Successful outcomes of SOT in the context of active TB are encouraging, including in patients with acute liver failure due to DILI associated with anti-TB drugs [55].

3. Conclusions

SOT is an important risk factor for TB reactivation and can often be prevented with screening and treatment of LTBI. Occasionally, TB can develop due to donor-derived infection. TB can

present differently in SOT recipients than in others; treatment is complicated by drug interactions and ADRs, though is usually successful.

Author Contributions

The authors both contributed to this article.

Funding

None.

Competing Interests

The authors have declared that no competing interests exist.

References

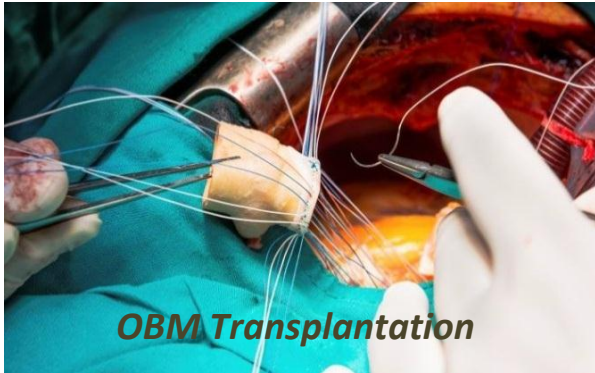
1. Weile J, Eickmeyer H, Dreier J, Liebke M, Fuchs U, Wittke JW, et al. First case of Mycobacterium tuberculosis transmission by heart transplantation from donor to recipient. *Int J Med Microbiol.* 2013; 303: 449-451.
2. Jung JY, Joo DJ, Lee CH, Park MS, Kim YS, Kim MS, et al. Pre-transplant risk factors for tuberculosis after kidney transplant in an intermediate burden area. *Int J Tuberc Lung Dis.* 2012; 16: 248-254.
3. Marques ID, Azevedo LS, Pierrotti LC, Caires RA, Sato VA, Carmo LP, et al. Clinical features and outcomes of tuberculosis in kidney transplant recipients in Brazil: a report of the last decade. *Clin Transplant.* 2013; 27: E169-E176.
4. Jeong JC, Koo TY, Jeon HJ, Park HC, Ryu HJ, Lee JP, et al. Utility of QuantiFERON-TB assay for prediction of tuberculosis development in kidney transplant patients in an intermediate-tuberculosis-burden country: lack of evidence for enhanced prediction for short-term tuberculosis development. *Transplant Proc.* 2014; 46: 583-587.
5. Lattes R, Radisic M, Rial M, Argento J, Casadei D. Tuberculosis in renal transplant recipients. *Transplant Infect Dis.* 1999; 1: 98-104.
6. Chen CY, Liu CJ, Feng JY, Loong CC, Liu C, Hsia CY, et al. Incidence and risk factors for tuberculosis after liver transplantation in an endemic area: A nationwide population-based matched cohort study. *Am J Transplant.* 2015; 15: 2180-2187.
7. Torre-Cisneros J, Doblaz A, Aguado JM, San Juan R, Blanes M, Montejo M, et al. Tuberculosis after solid-organ transplant: incidence, risk factors, and clinical characteristics in the RESITRA (Spanish Network of Infection in Transplantation) cohort. *Clin Infect Dis.* 2009; 48: 1657-1665.
8. Getahun H, Matteelli A, Chaisson RE, Raviglione M. Latent Mycobacterium tuberculosis infection. *N Engl J Med.* 2015; 372: 2127-2135.
9. Manuel O, Humar A, Preiksaitis J, Doucette K, Shokoples S, Peleg AY, et al. Comparison of quantiferon-TB gold with tuberculin skin test for detecting latent tuberculosis infection prior to liver transplantation. *Am J Transplant.* 2007; 7: 2797-2801.
10. Richeldi L, Losi M, D'Amico R, Luppi M, Ferrari A, Mussini C, et al. Performance of tests for latent tuberculosis in different groups of immunocompromised patients. *Chest.* 2009; 136: 198-204.

11. Kim SH, Lee SO, Park IA, Park SJ, Choi SH, Kim YS, et al. Diagnostic usefulness of a T cell-based assay for latent tuberculosis infection in kidney transplant candidates before transplantation. *Transplant Infect Dis*. 2010; 12: 113-119.
12. Soysal A, Toprak D, Koc M, Arikan H, Akoglu E, Bakir M. Diagnosing latent tuberculosis infection in haemodialysis patients: T-cell based assay (T-SPOT.TB) or tuberculin skin test? *Nephrol Dial Transplant*. 2012; 27: 1645-1650.
13. Ahmadinejad Z, Azmoudeh Ardalan F, Razzaqi M, Davoudi S, Jafarian A. QuantiFERON-TB Gold In-Tube test for diagnosis of latent tuberculosis (TB) infection in solid organ transplant candidates: a single-center study in an area endemic for TB. *Transplant Infect Dis*. 2013; 15: 90-95.
14. Kim SY, Jung GS, Kim SK, Chang J, Kim MS, Kim YS, et al. Comparison of the tuberculin skin test and interferon-gamma release assay for the diagnosis of latent tuberculosis infection before kidney transplantation. *Infection*. 2013; 41: 103-110.
15. Sester M, van Leth F, Bruchfeld J, Bumbacea D, Cirillo DM, Dilektasli AG, et al. Risk assessment of tuberculosis in immunocompromised patients. A TBNET study. *Am J Resp Crit Care Med*. 2014; 190: 1168-1176.
16. Edathodu J, Varghese B, Alrajhi AA, Shoukri M, Nazmi A, Elgamal H, et al. Diagnostic potential of interferon-gamma release assay to detect latent tuberculosis infection in kidney transplant recipients. *Transplant Infect Dis*. 2017; 19. doi: 10.1111/tid.12675.
17. Ferguson TW, Tangri N, Macdonald K, Hiebert B, Rigatto C, Sood MM, et al. The diagnostic accuracy of tests for latent tuberculosis infection in hemodialysis patients: a systematic review and meta-analysis. *Transplantation*. 2015; 99: 1084-1091.
18. Mazurek GH, Jereb J, Vernon A, LoBue P, Goldberg S, Castro K, et al. Updated guidelines for using Interferon Gamma Release Assays to detect Mycobacterium tuberculosis infection - United States, 2010. *MMWR Recommend Rep*. 2010; 59: 1-25.
19. Kim SH, Lee SO, Park JB, Park IA, Park SJ, Yun SC, et al. A prospective longitudinal study evaluating the usefulness of a T-cell-based assay for latent tuberculosis infection in kidney transplant recipients. *Am J Transplant*. 2011; 11: 1927-1935.
20. Anderson C, Inhaber N, Menzies D. Comparison of sputum induction with fiber-optic bronchoscopy in the diagnosis of tuberculosis. *Am J Resp Crit Care Med*. 1995; 152: 1570-1574.
21. Brown M, Varia H, Bassett P, Davidson RN, Wall R, Pasvol G. Prospective study of sputum induction, gastric washing, and bronchoalveolar lavage for the diagnosis of pulmonary tuberculosis in patients who are unable to expectorate. *Clin Infect Dis*. 2007; 44: 1415-1420.
22. Guirao-Arrabal E, Santos F, Redel-Montero J, Vaquero JM, Cantisan S, Vidal E, et al. Risk of tuberculosis after lung transplantation: the value of pretransplant chest computed tomography and the impact of mTOR inhibitors and azathioprine use. *Transplant Infect Dis*. 2016; 18: 512-519.
23. Lyu J, Lee SG, Hwang S, Lee SO, Cho OH, Chae EJ, et al. Chest computed tomography is more likely to show latent tuberculosis foci than simple chest radiography in liver transplant candidates. *Liver Transplant*. 2011; 17: 963-968.
24. Targeted tuberculin testing and treatment of latent tuberculosis infection. American Thoracic Society. *MMWR Recommend Rep*. 2000; 49: 1-51.

25. Adamu B, Abdu A, Abba AA, Borodo MM, Tleyjeh IM. Antibiotic prophylaxis for preventing post solid organ transplant tuberculosis. *Cochrane Database Syst Rev.* 2014. doi: 10.1002/14651858.CD008597.pub2.
26. Siskind MS, Thienemann D, Kirilin L. Isoniazid-induced neurotoxicity in chronic dialysis patients: report of three cases and a review of the literature. *Nephron.* 1993; 64: 303-306.
27. Sharma SK, Sharma A, Kadiravan T, Tharyan P. Rifamycins (rifampicin, rifabutin and rifapentine) compared to isoniazid for preventing tuberculosis in HIV-negative people at risk of active TB. *Cochrane Database Syst Rev.* 2013. doi: 10.1002/14651858.CD007545.pub2.
28. Menzies D, Adjobimey M, Ruslami R, Trajman A, Sow O, Kim H, et al. Four months of rifampin or nine months of isoniazid for latent tuberculosis in adults. *N Engl J Med.* 2018; 379: 440-453.
29. Oesch F, Arand M, Benedetti MS, Castelli MG, Dostert P. Inducing properties of rifampicin and rifabutin for selected enzyme activities of the cytochrome P-450 and UDP-glucuronosyltransferase superfamilies in female rat liver. *J Antimicrob Chemother.* 1996; 37: 1111-1119.
30. Finch CK, Chrisman CR, Baciewicz AM, Self TH. Rifampin and rifabutin drug interactions: an update. *Arch Intern Med.* 2002; 162: 985-992.
31. Hebert MF, Fisher RM, Marsh CL, Dressler D, Bekersky I. Effects of rifampin on tacrolimus pharmacokinetics in healthy volunteers. *J Clin Pharmacol.* 1999; 39: 91-96.
32. Reitman ML, Chu X, Cai X, Yabut J, Venkatasubramanian R, Zajic S, et al. Rifampin's acute inhibitory and chronic inductive drug interactions: experimental and model-based approaches to drug-drug interaction trial design. *Clin Pharmacol Ther.* 2011; 89: 234-242.
33. Hickey MD, Quan DJ, Chin-Hong PV, Roberts JP. Use of rifabutin for the treatment of a latent tuberculosis infection in a patient after solid organ transplantation. *Liver Transplant.* 2013; 19: 457-461.
34. Sterling TR, Villarino ME, Borisov AS, Shang N, Gordin F, Bliven-Sizemore E, et al. Three months of rifapentine and isoniazid for latent tuberculosis infection. *N Engl J Med.* 2011; 365: 2155-2166.
35. Belknap R, Holland D, Feng PJ, Millet JP, Cayla JA, Martinson NA, et al. Self-administered versus directly observed once-weekly isoniazid and rifapentine treatment of latent tuberculosis infection: A randomized trial. *Ann Intern Med.* 2017; 167: 689-697.
36. Borisov AS, Bamrah Morris S, Njie GJ, Winston CA, Burton D, Goldberg S, et al. Update of recommendations for use of once-weekly isoniazid-rifapentine regimen to treat latent mycobacterium tuberculosis infection. *MMWR Morb Mortal Wkly Rep.* 2018; 67: 723-726.
37. Sterling TR, Moro RN, Borisov AS, Phillips E, Shepherd G, Adkinson NF, et al. Flu-like and other systemic drug reactions among persons receiving weekly rifapentine plus isoniazid or daily isoniazid for treatment of latent tuberculosis infection in the prevent tuberculosis study. *Clin Infect Dis.* 2015; 61: 527-535.
38. Abad CLR, Razonable RR. Mycobacterium tuberculosis after solid organ transplantation: A review of more than 2000 cases. *Clin Transplant.* 2018; 32: e13259.
39. Jahng AW, Tran T, Bui L, Joyner JL. Safety of treatment of latent tuberculosis infection in compensated cirrhotic patients during transplant candidacy period. *Transplantation.* 2007; 83: 1557-1562.

40. Moon HH, Park SY, Kim JM, Park JB, Kwon CHD, Peck KR, et al. Isoniazid prophylaxis for latent tuberculosis infections in liver transplant recipients in a tuberculosis-endemic area. *Ann Transplant*. 2017; 22: 338-345.
41. Singh N, Wagener MM, Gayowski T. Safety and efficacy of isoniazid chemoprophylaxis administered during liver transplant candidacy for the prevention of posttransplant tuberculosis. *Transplantation*. 2002; 74: 892-895.
42. Bamrah S, Brostrom R, Dorina F, Setik L, Song R, Kawamura LM, et al. Treatment for LTBI in contacts of MDR-TB patients, Federated States of Micronesia, 2009-2012. *Int J Tuberc Lung Dis*. 2014; 18: 912-918.
43. Marks SM, Mase SR, Morris SB. Systematic Review, Meta-analysis, and cost-effectiveness of treatment of latent tuberculosis to reduce progression to multidrug-resistant tuberculosis. *Clin Infect Dis*. 2017; 64: 1670-1677.
44. Torre-Cisneros J, San-Juan R, Rosso-Fernandez CM, Silva JT, Munoz-Sanz A, Munoz P, et al. Tuberculosis prophylaxis with levofloxacin in liver transplant patients is associated with a high incidence of tenosynovitis: safety analysis of a multicenter randomized trial. *Clin Infect Dis*. 2015; 60: 1642-1649.
45. Tien V, Robilotti E, Callister D, Subramanian A, Lutchman G, Ho DY. Tolerability of fluoroquinolones in management of latent tuberculosis in liver transplant candidates. *Clin Infect Dis*. 2015; 61: 1631-1632.
46. Abad CLR, Razonable RR. Donor derived mycobacterium tuberculosis infection after solid-organ transplantation: A comprehensive review. *Transplant Infect Dis*. 2018; 20: e12971.
47. Morris MI, Daly JS, Blumberg E, Kumar D, Sester M, Schluger N, et al. Diagnosis and management of tuberculosis in transplant donors: a donor-derived infections consensus conference report. *Am J Transplant*. 2012; 12: 2288-2300.
48. Bodro M, Sabe N, Santin M, Cruzado JM, Llado L, Gonzalez-Costello J, et al. Clinical features and outcomes of tuberculosis in solid organ transplant recipients. *Transplant Proc*. 2012; 44: 2686-2689.
49. Chen SY, Wang CX, Chen LZ, Fei JG, Deng SX, Qiu J, et al. Tuberculosis in southern Chinese renal-transplant recipients. *Clin Transplant*. 2008; 22: 780-784.
50. Edathodu J, Alrajhi A, Halim M, Althawadi S. Multi-recipient donor-transmitted tuberculosis. *Int J Tuberc Lung Dis*. 2010; 14: 1493-1495.
51. Bucher JN, Schoenberg MB, Freytag I, Lange U, Hofmann-Thiel S, Guba MO, et al. Donor-derived tuberculosis after solid organ transplantation in two patients and a staff member. *Infection*. 2016; 44: 365-370.
52. Nahid P, Dorman SE, Alipanah N, Barry PM, Brozek JL, Cattamanchi A, et al. Official American Thoracic Society/Centers for Disease Control and Prevention/Infectious Diseases Society of America Clinical Practice Guidelines: Treatment of Drug-Susceptible Tuberculosis. *Clin Infect Dis*. 2016; 63: e147-e195.
53. Hohmann C, Kang EM, Jancel T. Rifampin and posaconazole coadministration leads to decreased serum posaconazole concentrations. *Clin Infect Dis*. 2010; 50: 939-940.
54. Li TY, Liu W, Chen K, Liang SY, Liu F. The influence of combination use of CYP450 inducers on the pharmacokinetics of voriconazole: A systematic review. *J Clin Pharm Ther*. 2017; 42: 135-146.

55. Lee YT, Hwang S, Lee SG, Kim KW, Choi NK, Park GC, et al. Living-donor liver transplantation in patients with concurrent active tuberculosis at transplantation. *Int J Tuberc Lung Dis.* 2010; 14: 1039-1044.



Enjoy *OBM Transplantation* by:

1. [Submitting a manuscript](#)
2. [Joining in volunteer reviewer bank](#)
3. [Joining Editorial Board](#)
4. [Guest editing a special issue](#)

For more details, please visit:

<http://www.lidsen.com/journals/transplantation>