

Case Report

**Clival Paraganglioma, Case Report and Literature Review**

Rachel Moor <sup>1</sup>, Michael Goutnik <sup>1</sup>, Brandon Lucke-Wold <sup>1,\*</sup>, Dimitri Laurent <sup>1</sup>, Si Chen <sup>2</sup>, William Friedman <sup>1</sup>, Maryam Rahman <sup>1</sup>, Nichole Allen <sup>3</sup>, Marie Rivera-Zengotita <sup>3</sup>, Matthew Koch <sup>1</sup>

1. Department of Neurosurgery, University of Florida, Gainesville, USA; E-Mails: [rachel.moor@neurosurgery.ufl.edu](mailto:rachel.moor@neurosurgery.ufl.edu); [mgoutnik@ufl.edu](mailto:mgoutnik@ufl.edu); [Brandon.Lucke-Wold@neurosurgery.ufl.edu](mailto:Brandon.Lucke-Wold@neurosurgery.ufl.edu); [Dimitri.Laurent@neurosurgery.ufl.edu](mailto:Dimitri.Laurent@neurosurgery.ufl.edu); [friedman1@neurosurgery.ufl.edu](mailto:friedman1@neurosurgery.ufl.edu); [maryam.rahman@neurosurgery.ufl.edu](mailto:maryam.rahman@neurosurgery.ufl.edu); [matthew.koch@neurosurgery.ufl.edu](mailto:matthew.koch@neurosurgery.ufl.edu)
2. Department of Otolaryngology, University of Florida, Gainesville, USA; E-Mail: [si.chen@ent.ufl.edu](mailto:si.chen@ent.ufl.edu)
3. Department of Pathology, University of Florida, Gainesville, USA; E-Mails: [allenn1@ufl.edu](mailto:allenn1@ufl.edu); [mriveraz@ufl.edu](mailto:mriveraz@ufl.edu)

\* **Correspondence:** Brandon Lucke-Wold; E-Mail: [Brandon.Lucke-Wold@neurosurgery.ufl.edu](mailto:Brandon.Lucke-Wold@neurosurgery.ufl.edu)

**Academic Editor:** Tomohiro Chiba

*OBM Neurobiology*

2022, volume 6, issue 3

doi:10.21926/obm.neurobiol.2203128

**Received:** May 30, 2022

**Accepted:** July 04, 2022

**Published:** July 07, 2022

**Abstract**

Paragangliomas are rare tumors that may present with cranial neuropathies when located along the skull base. Supratentorial paragangliomas are less likely to secrete catecholamines but should be worked up, nonetheless. We highlight a case of a female in her fourth decade found to have a petroclival lesion following initial presentation that included one month of tooth pain, dysphagia, diplopia, hoarseness and right hemifacial hypoesthesia. Magnetic resonance imaging of the brain demonstrated a T2 hyperintense lesion favored to be a petroclival meningioma. Pre-operative angiography demonstrated a hypervascular tumor. She underwent a combined presigmoid craniotomy with posterior petrosectomy performed by both neurosurgery and neuro-otology. Pathology demonstrated paraganglioma. She had small volume residual tumor and is planned for continued outpatient radiotherapy. Paragangliomas should be on the differential for skull base lesions. Management paradigm involves



© 2022 by the author. This is an open access article distributed under the conditions of the [Creative Commons by Attribution License](https://creativecommons.org/licenses/by/4.0/), which permits unrestricted use, distribution, and reproduction in any medium or format, provided the original work is correctly cited.

multidisciplinary care and a combination of surgical resection and post-operative radiation. In this paper, we discuss underlying pathophysiology as well as appropriate workup and management.

### **Keywords**

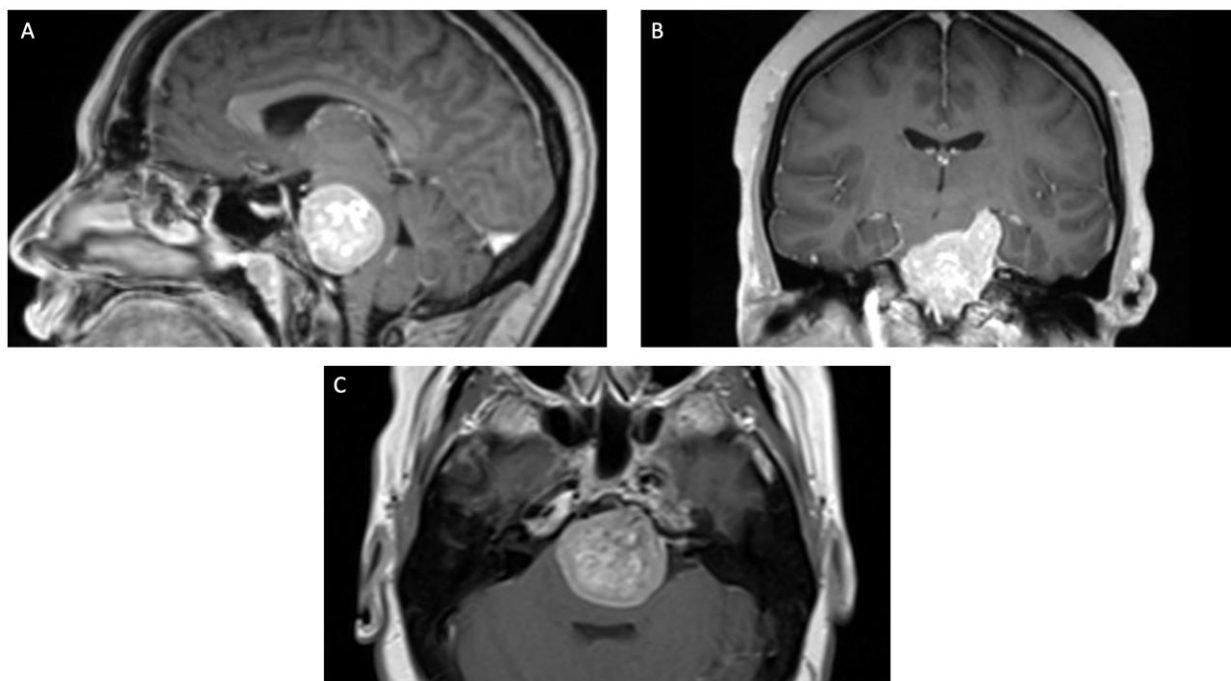
Paraganglioma; catecholamine; surgical resection; radiation; clinical work up

## **1. Introduction**

Paragangliomas of the head and neck arise from chromaffin cells of parasympathetic paraganglia and often have variable catecholamine release [1]. These tumors can mimic other lesions such as meningiomas and solitary fibrous tumors. Most common locations for head and neck paragangliomas include the carotid body and the jugular foramen, Work up starts with imaging, which typically consists of MRI followed by angiography if high vascularity is suspected [2]. New onset cranial neuropathy is a common clinical presentation of skull base paragangliomas owing to local mass effect [3]. Once suspected, catecholamine release assays should be performed to determine the efficacy of pre-operative medical treatment with agents such as phenoxybenzamine, propranolol, or metyrosine. Current practice consists of diagnostic angiography with or without embolization, surgical resection of lesion, and post-operative radiation if gross total resection was not achieved [4]. Depending on location of lesion, the surgical resection is often a combined approach with otolaryngology and neurosurgery [5]. For glomus jugulare tumors, radiation therapy or radiosurgery in the most common approach. The differential diagnosis for a petroclival tumor includes meningioma, schwannoma of nearby cranial nerves, chondroma, chondrosarcoma, chordoma, and others. These lesions can present with subtle onset of symptoms, including cranial neuropathies and signs/symptoms of elevated intracranial pressure [6]. In this paper, we present a unique case of a petroclival paraganglioma. We discussed the intricacies of workup and management. In the discussion, we highlight the important teaching points regarding pathology, genetic contribution, and long-term outcomes with appropriate follow up.

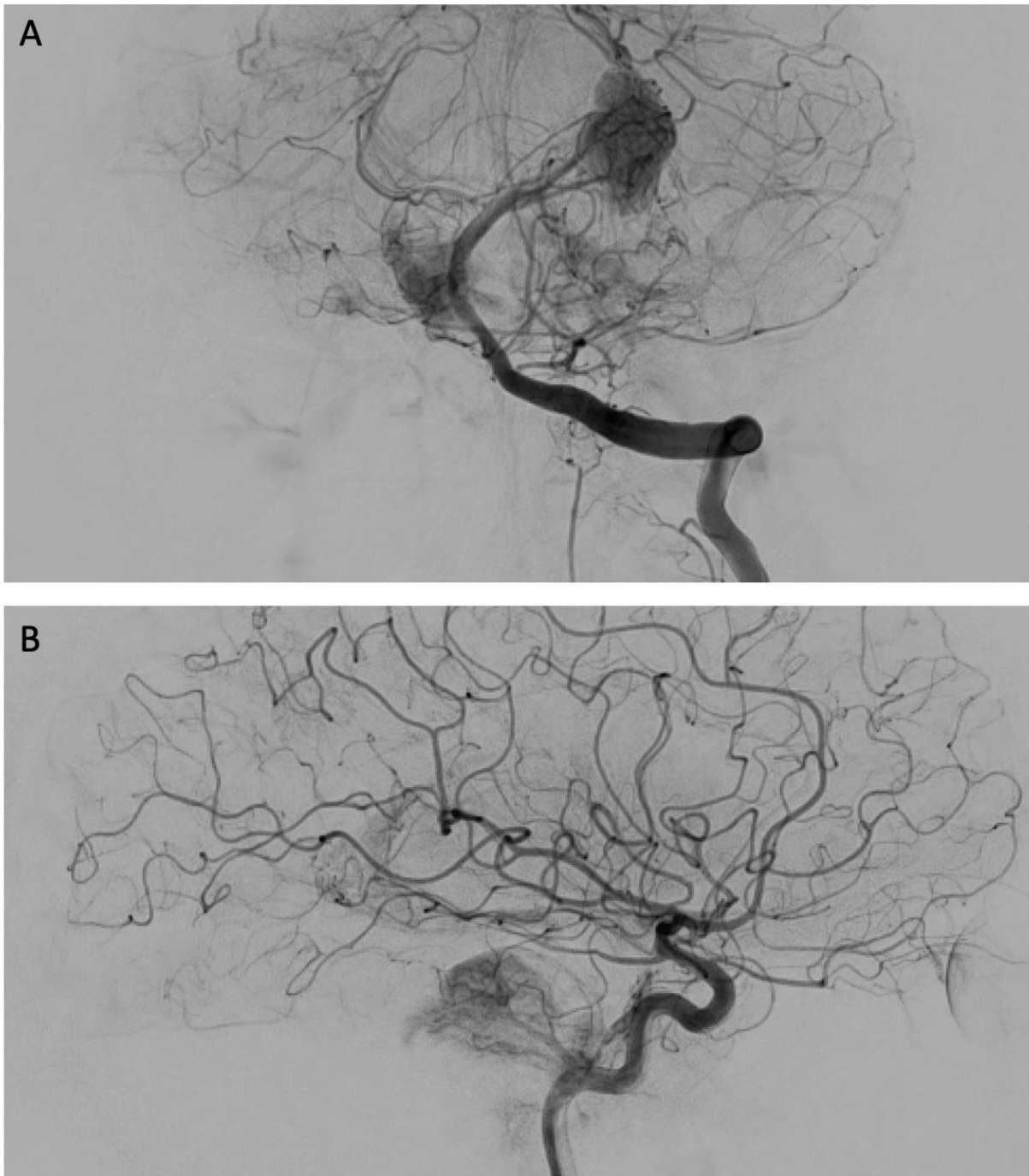
## **2. Case**

A woman presented in her fourth decade with one month of tooth pain, dysphagia, diplopia, hoarseness, and right hemifacial hypoesthesia. She also reported diminished manual dexterity bilaterally and gait instability. Physical exam was notable for dysconjugate gaze with abduction of the left eye, incomplete left lateral gaze palsy, decreased sensation throughout the face bilaterally, and a House-Brackmann Grade II left facial nerve palsy. Audiogram demonstrated normal hearing and laryngoscopy demonstrated normal vocal cord function. MRI brain demonstrated an avidly enhancing and T2 hyperintense retroclival mass with significant mass effect on the adjacent brainstem, cranial nerves, and vascular structures (Figure 1).

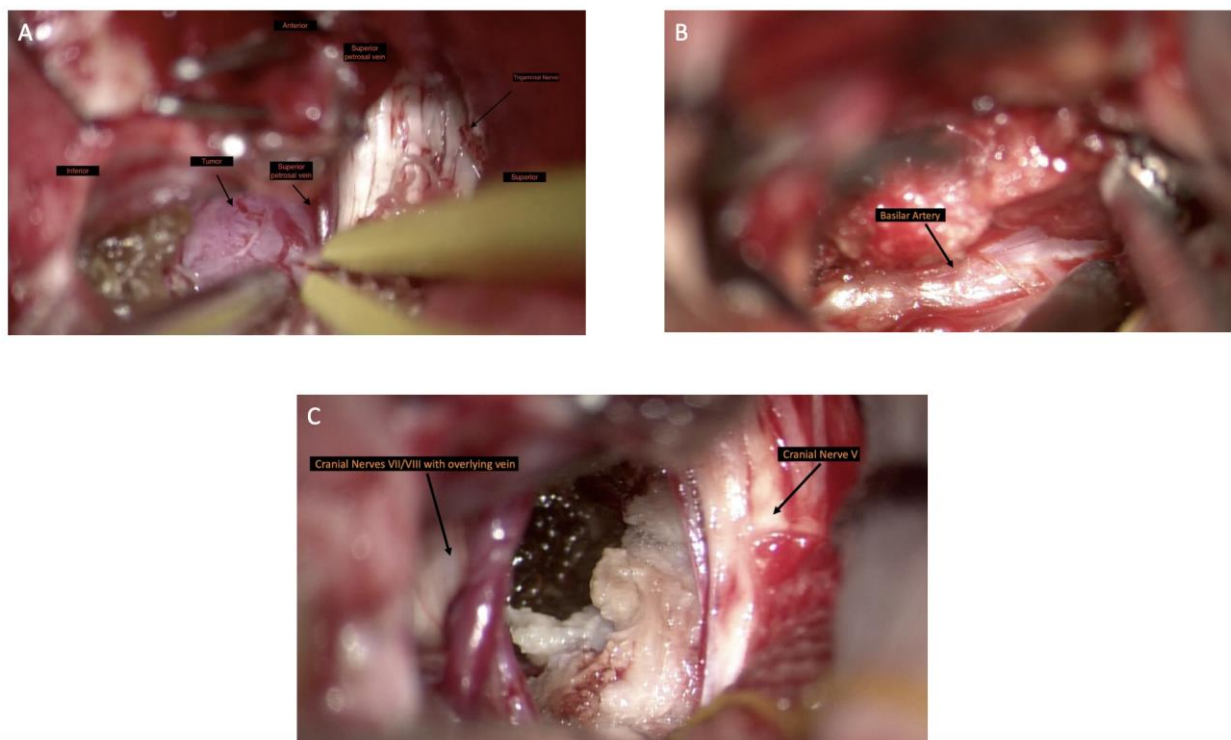


**Figure 1** T1 postcontrast MRI demonstrating an avidly enhancing extra-axial clival tumor with brainstem compression. A, Sagittal. B, Coronal. C, Axial.

Given the patient's progressive symptoms and the lesion's compression of nearby neurovascular anatomy, the patient was recommended for surgical resection. Preoperatively, the patient underwent preoperative angiography to better delineate the tumor's relationship to the posterior circulation (Figure 2). A hypervascular lesion with brisk vascular supply of the lesion via petrous cavernous branches of the bilateral internal carotid arteries, right and left external carotids, and posterior circulation, with evidence of tumoral shunting. The microvasculature was difficult to access limiting preoperative embolization. She underwent preoperative placement of an external ventricular drain with plan for rapid wean post surgery. The following day, she underwent a combined left extended retrosigmoid craniotomy, temporal craniotomy, and posterior petrosectomy with neurosurgery and neuro-otology with stereotaxy, SSEP, MEP, and monitoring of cranial nerves V, VII, VIII, IX and X. This approach was chosen to minimize retraction of normal cerebellum in this young patient, as well as to provide access to both the supratentorial and infratentorial compartments (Figure 3).

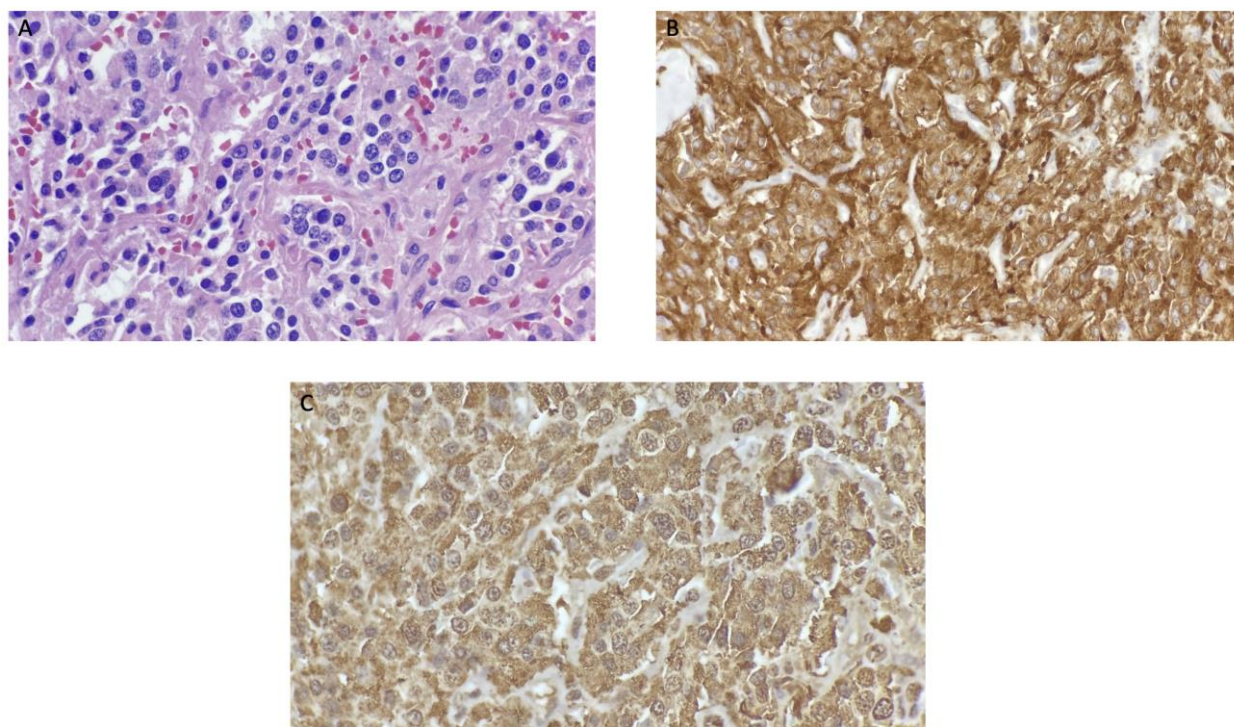


**Figure 2** Multiple views of angiogram demonstrating brisk filling of the tumor via anterior and posterior circulation. A, Left vertebral artery run, AP view. B, Right internal carotid artery run, lateral view.



**Figure 3** A-C, Intraoperative findings of clival paraganglioma, including cranial nerve V, the cranial nerve VII/VIII complex, and the basilar artery with adherent tumor.

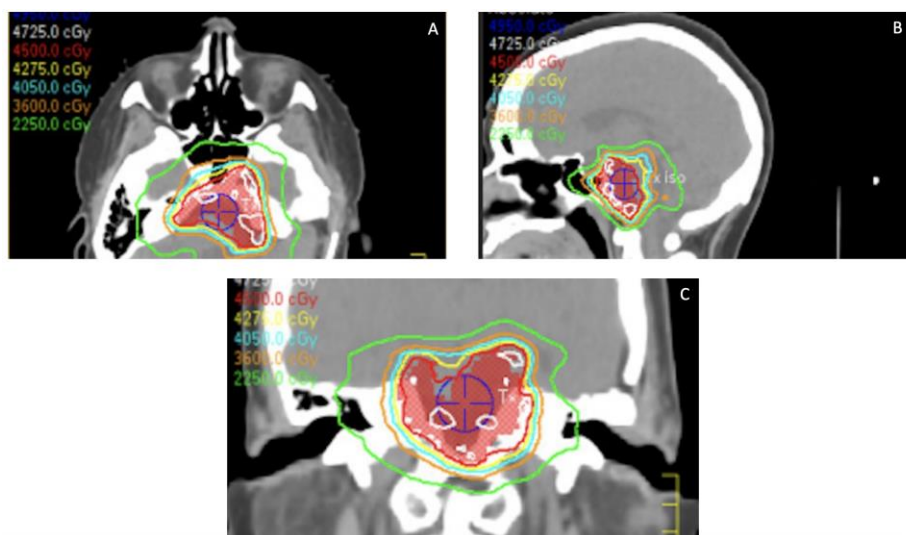
Postoperatively, the patient woke with a stable left House-Brackmann Grade II facial nerve palsy. She also had left CN VI palsy, diminished facial sensation in the V1 and V2 distribution, and left ear sensorineural hearing loss confirmed by audiogram. Postoperative MRI demonstrated small volume residual tumor along the left petroclival junction. Pathologic examination revealed fibrous tissue consisting of nests and clusters of cells that display hyperchromatic nuclei, coarsely granular chromatin, and moderate to abundant eosinophilic cytoplasm. Tumor cells are diffusely and strongly immunoreactive for synaptophysin and chromogranin. This pathologic profile was consistent with a paraganglioma (Figure 4). Additionally, the pathologic examination revealed a prominent vascular component, as expected based on preoperative angiogram findings. Given the neuroendocrinologic origin of the tumor, a metastatic workup was undertaken, which was negative.



**Figure 4** Pathology demonstrating fibrous tissue consisting of nests and clusters of cells that display hyperchromatic nuclei, coarsely granular chromatin and moderate to abundant eosinophilic cytoplasm. A, H&E (40 $\times$ ). B, Synaptophysin stain. C, Chromogranin stain.

The patient had ventilator dependent respiratory failure postoperatively and underwent a tracheostomy. She was subsequently able to be weaned from the ventilator and her tracheostomy was downsized and decannulated prior to discharge from the hospital.

One month postoperative, MRI brain demonstrates stable residual. A discussion regarding management of residual was held with the patient and a multi-disciplinary tumor board, and the decision was made to refer to radiation oncology for fractionated conformal radiotherapy of small residual disease (Figure 5). She has had follow up with neurosurgery, neurotology, and endocrinology. She has ophthalmology consultation and genetic testing pending. Her neurologic status remains stable, with improving left hemifacial numbness, a left CN VI palsy, left HB II CN VII palsy, and left sensorineural hearing loss.



**Figure 5** A-C, Fractionated radiation treatment planning.

### 3. Discussion

#### 3.1 Epidemiology

Head and neck paragangliomas are rare, accounting for about 0.6% of head and neck tumors [7]. Paragangliomas usually present between age 30-60 (mean age 47) [8]. Erickson et al. studied 236 patients, noting that most (69%) of paragangliomas are found in the head and neck rather than below the neck [8]. However, most catecholamine-secreting paragangliomas are found in the abdomen and pelvis, while less than 5% of head and neck paragangliomas secrete catecholamines [8, 9]. Catecholamine secretion may be associated with headache and episodic hypertension, and can even occasionally lead to extreme increases in blood pressure that result in cardiovascular collapse [9]. Furthermore, long-term follow up is important for patients with paragangliomas, as one-third of patients have persistent or recurrent paragangliomas [8]. Malignant paraganglioma is defined by metastasis to non-neuroendocrine tissue (often cervical lymph nodes) [9]. Fewer than 10% of head and neck paragangliomas appear malignant [7, 10]. However, tumor location may influence metastatic rate, with vagal tumors having malignancy rates as high as 19% [7, 11].

Paragangliomas in the head and neck region present with mass effect rather than catecholamine excess [8, 12]. Frequent presenting symptoms include neck mass, tinnitus, and cranial nerve palsies similar to that seen in our patient [8]. Effects depend on the location of the tumor. For example, carotid body and vagal body paragangliomas are among the most common head and neck paragangliomas, usually presenting as a painless neck mass [8, 12-14]. In contrast, jugulotympanic paragangliomas are usually less common, presenting with progressive hearing loss or tinnitus [8, 12-14]. Jugulotympanic paragangliomas are also most likely to persist following surgical treatment, so yearly urinary metanephrine excretion monitoring is essential [8].

#### 3.2 Pathophysiology

The paraganglion system is an important source of catecholamines during fetal development, and typically regresses after birth, leaving sparse autonomic nervous system cells in the carotid, aorticopulmonary system, jugular body, and other anatomic locations [15-18]. These cells act as

chemoreceptors and/or secrete catecholamines during stress. Some genetic predisposition leads to failure of regress of these cells resulting in a paraganglioma. Paragangliomas are rare, often benign vascular tumors that originate from overgrowth of chromaffin cells of the paraganglia [15, 18]. An overview the genetic predisposition is summarized below.

A large study of 501 Italian patients with secreting and nonsecreting paragangliomas found germline mutations in about 32% of cases [19]. The most common being *RET*, *VHL*, *SDHB*, and *SDHD* mutations [20]. *RET* predisposes to transcriptomic clusters that activate kinase pathways to facilitate cell division [21]. *VHL* mutations are part of the pseudohypoxia driven cluster that stabilize cell growth. *SDHB* mutations activate malignant conversion and are frequently associated with pheochromocytomas [19, 22]. *SDHD* mutation leads to more head and neck paragangliomas in particular [19, 22]. A postulated mechanisms is that this gene encodes a subunit of the mitochondrial succinate dehydrogenase complex and that allows chromaffin cells to survive in a hypoxic state [23].

### 3.3 Imaging

Functional imaging is highly capable of finding specific lesions by using tumor-specific ligands connected to radiotracers [24, 25]. Iodine 123 meta-iodobenzylguanidine (<sup>123</sup>I-MIBG) was traditionally used for pheochromocytoma and paraganglioma detection, but has been surpassed by newer positron emission tomography (PET) modalities [26]. Head and neck paragangliomas may be more effectively visualized via [<sup>68</sup>Ga]-DOTATATE PET/CT compared to standard imaging modalities, including the current gold standard [<sup>18</sup>F]-FDOPA) PET/CT [24]. This functional imaging modality relies on paraganglioma overexpression of somatostatin receptors, which [<sup>68</sup>Ga]-DOTA-peptides bind effectively [24]. Furthermore, [<sup>68</sup>Ga]-DOTATATE PET/CT is more effective in detecting head and neck paraganglioma metastases, compared to [<sup>18</sup>F]-FDOPA) PET/CT and traditional PET/CT [25].

### 3.4 Skull Base Paragangliomas

While glomus jugulare tumors are technically of the skull base, other paragangliomas of the skull base are quite rare. Paraganglioma cases involving the skull base outside the jugular foramen described in the literature have a variety of clinical presentations [27-33]. Understanding the breadth of presentation will aid in early diagnosis and effective initiation of treatment. Table 1 summarizes 7 paraganglioma cases with clival involvement.

**Table 1** Case Reports of Clival Paragangliomas.

Study	Patient Age and Gender	Anatomical Location	Symptoms	Additional Unique Findings
Noble et al. [34] (1997)	71 year old man	Sella, with destruction of clivus, extension into cavernous sinuses, encasement of internal carotid	Bitemporal hemianopsia and anosmia	Several large cysts with “crankcase-type” fluid were found during surgery. This tumor was massive and involved encasement of major vessels and compression of optic nerves, chiasm, and brain stem.



---

		arteries, and displacement of basilar artery posteriorly		
Hertel et al. [35] (2003)	51 year old woman	Anterior, middle, and posterior cranial fossa with extended destruction of skull base, including the clivus	Long-standing headaches, 2 months of dizziness, one month of left facial nerve paresis	Patient did well following another resection, VP shunt for hydrocephalus, and fractionated stereotactic radiosurgery, with a new incomplete third-nerve paresis and need for complete hormonal substitution.
Bijlenga et al. [30] (2004)	44 year old man	Nasopharynx with clival extension	Recurrent (>2 years) unilateral epistaxis	Head and neck, neurological, and ophthalmological evaluations were unremarkable.
Ünal et al. [27] (2007)	75 year old woman	Clivus	Mild facial paresis (House-Brackman Grades 1-2), accessory, and hypoglossal paralysis on right side	The patient refused radiotherapy treatment following biopsy, and did not experience progression at one year follow up.
Ruzevick et al. [29] (2017)	69 year old woman	Clivus	Diplopia (3 months)	An initial endoscopic endonasal approach was complicated by bleeding and hypertensive crisis, which was concerning for excess catecholamine secretion. Serum normetanephrines were found to be elevated, leading to embolization of arterial feeders followed by phenoxybenzamine treatment and resection of the tumor. Because of continued elevation of serum normetanephrines, proton beam radiotherapy was started as adjuvant treatment.

---

Ruzevick et al. [29] (2017)	65 year old man	Clivus and sphenoid sinus, with both carotid arteries encapsulated	Mild right foot drop	Following endoscopic endonasal approach for biopsy and post-operative urinary catecholamine measurement confirming a non-secretory paraganglioma, spontaneous involution of the mass was noted on MRI.
Okasha et al. [28] (2021)	Unknown	Clivus	Abducens nerve palsy	

### 3.5 Treatment

The British Skull Base Society recently established a consensus for management of skull based paragangliomas. The consensus recommendations include multidisciplinary management, endocrine assessment, genetic assessment, and MRI of the head, neck, abdomen, and pelvis. Observation is reasonable for asymptomatic patients without catecholamine surges [36]. For symptomatic lesions with cranial nerve deficits, surgery is a viable alternative with suggested pre-operative embolization [3, 8, 14, 37]. However, for non-resectable lesions radiotherapy may achieve tumor control with less morbidity, as attempted debulking may induce cranial nerve palsy [38-42]. In fact, tailored resection followed by radiosurgery may lead to more favorable outcomes in terms of tumor size and preventing cranial neuropathy [43]. If the residual lesion is irregular or encases cranial nerves, fractionated radiotherapy may be the more amenable option. The primary goal should be debulking to relieve pressure from the brain stem and cranial nerves. Factors like tumor location, size, and secretory status of the tumor influence the treatment choice. Radiation is often an appropriate first line treatment for tumors in typical locations; however, lesions like our patient’s in more atypical locations require resection for decompression and tissue diagnosis. For secretory paragangliomas, anti-hypertensive medications are first line and should be initiated prior to surgical resection to carefully control blood pressure.

### 4. Conclusions

We present a unique case of a paraganglioma that mimicked a meningioma in that it was homogeneously enhancing and appeared attached to the dura. MRI is the investigation of choice with typical findings for paraganglioma including a well-circumscribed, intensely enhancing mass lesion with few areas of cystic compartments. T2-weighted imaging (T2WI) occasionally will show a “cap sign” or “salt and pepper” appearance. When differential is in question, PET/CT may be helpful to differentiate. Once recognized, catecholamine levels should be measured and attempted resection with embolization of arterial feeders should be performed. Depending on approach and/or adherence to cranial nerves, residual can be treated with radiation therapy. Patients should be monitored closely and counseled appropriately regarding expected deficits and recovery.

## Author Contributions

RM and MG wrote introduction, BL formulated paper and helped write discussion with DL. SC, WF, MR provided expert guidance on surgical approach. NA and MR assisted with pathology analysis. MK performed the surgery and provided expert guidance on case write up.

## Competing Interests

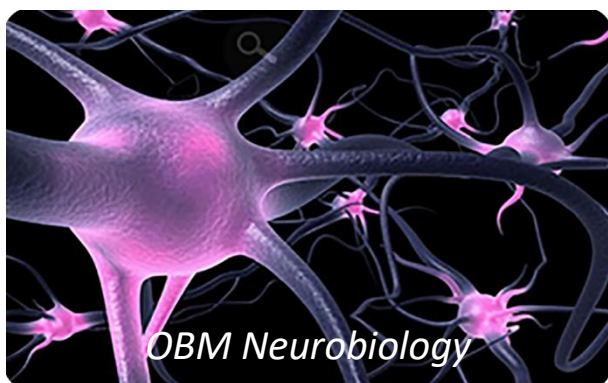The authors have declared that no competing interests exist.

## References

1. Ikram A, Rehman A. Paraganglioma. Treasure Island: StatPearls Publishing; 2021.
2. Reith W, Kettner M. Diagnostik und Therapie von Glomustumoren der Schädelbasis und des Halses. *Der Radiologe*. 2019; 59: 1051-1057.
3. Catapano JS, Almefty RO, Ding D, Whiting AC, Pines AR, Richter KR, et al. Onyx embolization of skull base paragangliomas: A single-center experience. *Acta Neurochir (Wien)*. 2020; 162: 821-829.
4. Mori Y, Kida Y, Matsushita Y, Mizumatsu S, Hatano M. Stereotactic radiosurgery and stereotactic radiotherapy for malignant skull base tumors. *Cureus*. 2020; 12: e8401.
5. Isaacson B, Killeen DE, Bianconi L, Marchioni D. Endoscopic assisted lateral skull base surgery. *Otolaryngol Clin North Am*. 2021; 54: 163-173.
6. McElveen JT, Dorfman BE, Fukushima T. Petroclival tumors: A synthesis. *Otolaryngol Clin North Am*. 2001; 34: 1219-1230.
7. Lee JH, Barich F, Karnell LH, Robinson RA, Zhen WK, Gantz BJ, et al. National cancer data base report on malignant paragangliomas of the head and neck. *Cancer*. 2002; 94: 730-737.
8. Erickson D, Kudva YC, Ebersold MJ, Thompson GB, Grant CS, van Heerden JA, et al. Benign paragangliomas: Clinical presentation and treatment outcomes in 236 patients. *J Clin Endocrinol Metab*. 2001; 86: 5210-5216.
9. Lee JA, Duh QY. Sporadic paraganglioma. *World J Surg*. 2008; 32: 683-687.
10. Mediouni A, Ammari S, Wassef M, Gimenez-Roqueplo AP, Laredo JD, Duet M, et al. Malignant head/neck paragangliomas. Comparative study. *Eur Ann Otorhinolaryngol Head Neck Dis*. 2014; 131: 159-166.
11. Druck NS, Spector GJ, Ciralsky RH, Ogura JH. Malignant glomus vagale: Report of a case and review of the literature. *Arch Otolaryngol*. 1976; 102: 634-636.
12. Lack EE, Cubilla AL, Woodruff JM, Farr HW. Paragangliomas of the head and neck region: A clinical study of 69 patients. *Cancer*. 1977; 39: 397-409.
13. Lack EE, Cubilla AL, Woodruff JM. Paragangliomas of the head and neck region: A pathologic study of tumors from 71 patients. *Hum Pathol*. 1979; 10: 191-218.
14. Persky MS, Setton A, Niimi Y, Hartman J, Frank D, Berenstein A. Combined endovascular and surgical treatment of head and neck paragangliomas—A team approach. *Head Neck*. 2002; 24: 423-431.
15. Baysal BE. Hereditary paraganglioma targets diverse paraganglia. *J Med Genet*. 2002; 39: 617-622.

16. Boedeker CC, Ridder GJ, Schipper J. Paragangliomas of the head and neck: Diagnosis and treatment. *Fam Cancer*. 2005; 4: 55-59.
17. Kumar P, Prabhakar NR. Peripheral chemoreceptors: Function and plasticity of the carotid body. *Compr Physiol*. 2012; 2: 141-219.
18. Wasserman PG, Savargaonkar P. Paragangliomas: Classification, pathology, and differential diagnosis. *Otolaryngol Clin North Am*. 2001; 34: 845-862.
19. Mannelli M, Castellano M, Schiavi F, Filetti S, Giacchè M, Mori L, et al. Clinically guided genetic screening in a large cohort of Italian patients with pheochromocytomas and/or functional or nonfunctional paragangliomas. *J Clin Endocrinol Metab*. 2009; 94: 1541-1547.
20. Neumann HP, Bausch B, McWhinney SR, Bender BU, Gimm O, Franke G, et al. Germ-line mutations in nonsyndromic pheochromocytoma. *N Engl J Med*. 2002; 346: 1459-1466.
21. Dahia PLM. Pheochromocytoma and paraganglioma pathogenesis: Learning from genetic heterogeneity. *Nat Rev Cancer*. 2014; 14: 108-119.
22. Benn DE, Gimenez-Roqueplo AP, Reilly JR, Bertherat J, Burgess J, Byth K, et al. Clinical presentation and penetrance of pheochromocytoma/paraganglioma syndromes. *J Clin Endocrinol Metab*. 2006; 91: 827-836.
23. Baysal BE, Ferrell RE, Willett-Brozick JE, Lawrence EC, Mysiorek D, Bosch A, et al. Mutations in SDHD, a mitochondrial complex II gene, in hereditary paraganglioma. *Science*. 2000; 287: 848-851.
24. Janssen I, Chen CC, Taieb D, Patronas NJ, Millo CM, Adams KT, et al. 68GA-DOTATATE PET/CT in the localization of head and neck paragangliomas compared with other functional imaging modalities and CT/MRI. *J Nucl Med*. 2016; 57: 186-191.
25. Lin EP, Chin BB, Fishbein L, Moritani T, Montoya SP, Ellika S, et al. Head and neck paragangliomas: An update on the molecular classification, state-of-the-art imaging, and management recommendations. *Radiol Imaging Cancer*. 2022; 4: e210088.
26. Fishbein L, Del Rivero J, Else T, Howe JR, Asa SL, Cohen DL, et al. The North American neuroendocrine tumor society consensus guidelines for surveillance and management of metastatic and/or unresectable pheochromocytoma and paraganglioma. *Pancreas*. 2021; 50: 469-493.
27. Ünal M, Polat A, Pata YS, Vayisoğlu Y, Yildiz A, Ismi O. Paraganglioma of the skull base: A case report. *Auris Nasus Larynx*. 2007; 34: 427-430.
28. Okasha M, Abougamil A, Raslan A, Roy A, Bodi I, Maratos E, et al. Endoscopic endonasal approach to rare clival paraganglioma: Case report and review of literature. *SN Compr Clin Med*. 2021; 3: 2688-2693.
29. Ruzevick J, Koh EK, Gonzalez-Cuyar LF, Cimino PJ, Moe K, Wright LA, et al. Clival paragangliomas: A report of two cases involving the midline skull base and review of the literature. *J Neurooncol*. 2017; 132: 473-478.
30. Bijlenga P, Dulguerov P, Richter M, de Tribolet N. Nasopharynx paraganglioma with extension in the clivus. *Acta Neurochir (Wien)*. 2004; 146: 1355-1359.
31. Singh S, Kumar A, Mehrotra A, Rao RN, Behari S. Nonsecretory paraganglioma in cavernous sinus masquerading as meningioma. *World Neurosurg*. 2019; 126: 399-404.
32. Sinha S, Sharma MC, Sharma BS. Malignant paraganglioma of the sellar region mimicking a pituitary macroadenoma. *J Clin Neurosci*. 2008; 15: 937-939.

33. Steel TR, Dailey AT, Born D, Berger MS, Mayberg MR. Paragangliomas of the sellar region: Report of two cases. *Neurosurgery*. 1993; 32: 844-847.
34. Noble ER, Smoker WR, Ghatak NR. Atypical skull base paragangliomas. *AJNR Am J Neuroradiol*. 1997; 18: 986-990.
35. Hertel F, Bettag M, Mörsdorf M, Feiden W. Paragangliomas of the parasellar region. *Neurosurg Rev*. 2003; 26: 210-214.
36. van der Mey AG, Frijns JH, Cornelisse CJ, Brons EN, van Dulken H, Terpstra HL, et al. Does intervention improve the natural course of glomus tumors? A series of 108 patients seen in a 32-year period. *Ann Otol Rhinol Laryngol*. 1992; 101: 635-642.
37. Lloyd S, Obholzer R, Tysome J, Group BC. British skull base society clinical consensus document on management of head and neck paragangliomas. *Otolaryngol Head Neck Surg*. 2020; 163: 400-409.
38. Huy PT, Kania R, Duet M, Dessard-Diana B, Mazon JJ, Benhamed R. Evolving concepts in the management of jugular paraganglioma: A comparison of radiotherapy and surgery in 88 cases. *Skull Base*. 2009; 19: 83-91.
39. Sharma MS, Gupta A, Kale SS, Agrawal D, Mahapatra AK, Sharma BS. Gamma knife radiosurgery for glomus jugulare tumors: Therapeutic advantages of minimalism in the skull base. *Neurol India*. 2008; 56: 57-61.
40. Gilbo P, Morris CG, Amdur RJ, Werning JW, Dziegielewski PT, Kirwan J, et al. Radiotherapy for benign head and neck paragangliomas: A 45-year experience. *Cancer*. 2014; 120: 3738-3743.
41. Chino JP, Sampson JH, Tucci DL, Brizel DM, Kirkpatrick JP. Paraganglioma of the head and neck: Long-term local control with radiotherapy. *Am J Clin Oncol*. 2009; 32: 304-307.
42. Suárez C, Rodrigo JP, Bödeker CC, Llorente JL, Silver CE, Jansen JC, et al. Jugular and vagal paragangliomas: Systematic study of management with surgery and radiotherapy. *Head Neck*. 2013; 35: 1195-1204.
43. Miller JP, Semaan M, Einstein D, Megerian CA, Maciunas RJ. Staged gamma knife radiosurgery after tailored surgical resection: A novel treatment paradigm for glomus jugulare tumors. *Stereotact Funct Neurosurg*. 2009; 87: 31-36.



Enjoy *OBM Neurobiology* by:

1. [Submitting a manuscript](#)
2. [Joining in volunteer reviewer bank](#)
3. [Joining Editorial Board](#)
4. [Guest editing a special issue](#)

For more details, please visit:

<http://www.lidsen.com/journals/neurobiology>