

Case Report

Becker Phenotype Muscular Dystrophy in a Man with Klinefelter Syndrome: A Rare Association

Arianne Llamas-Paneque ^{1, *}, Isabel Echevarría-Frutos ², Amaury León-Sosa ², Tanja Herrmann ³, Thomas Liehr ³

1. School of Dentistry, Sciences of Life Faculty, International University of Ecuador, Jorge Fernández S/N, Quito 170411, Ecuador; E-Mail: arllanospa@uide.edu.ec; ORCID: 0000-0002-7161-1787
2. Medicine School, Technological Israel University, E4-142, Marieta De Veintimilla y Fco. Pizarro, Quito 170516, Ecuador; E-Mails: iechevarria@uisrael.edu.ec; aleon@uisrael.edu.ec
3. Institute of Human Genetics, Jena University Hospital, Am Klinikum 1, D-07747 Jena, Germany; E-Mails: tanja.Herrmann@med.uni-jena.de; thomas.Liehr@med.uni-jena.de

* **Correspondence:** Arianne Llamas-Paneque; E-Mail: arllanospa@uide.edu.ec; ORCID: 0000-0002-7161-1787

Academic Editor: Darren Griffin

Collection: [Genetic Testing](#)

OBM Genetics

2024, volume 8, issue 3

doi:10.21926/obm.genet.2403262

Received: July 08, 2024

Accepted: September 20, 2024

Published: September 26, 2024

Abstract

To present a rare clinical case of a man affected simultaneously by Becker phenotype Muscular Dystrophy (*MD*) and Klinefelter syndrome and the way how he was diagnosed. A 35-year-old man was evaluated in the context of hospitalization for respiratory failure. Since childhood, he had a clinical and muscle biopsy diagnosis of muscular dystrophy, possibly type Becker. His physical examination showed severe weakness of the pelvic and shoulder girdle, with a waddling gait, grade II scoliosis associated with tall height, obesity, and hypogonadism. Banding cytogenetics detected a sexual trisomy, 47, XXY in ~64% of peripheral blood cells. A heterozygote missense mutation in the dystrophin gene (*DMD*) was found in parallel using next-generation sequencing. Biparental origin, both X chromosomes suggest nondisjunction in paternal meiosis I, followed by a postzygotic trisomic rescue in a subset of fetal cells during



© 2024 by the author. This is an open access article distributed under the conditions of the [Creative Commons by Attribution License](#), which permits unrestricted use, distribution, and reproduction in any medium or format, provided the original work is correctly cited.

embryonic development. Maternal inheritance of the *DMD* gene mutation was excluded, suggesting a *de novo* origin. This is the eighth case where Klinefelter syndrome and Becker phenotype Muscular Dystrophy are parallel. As the patient presents with relatively mild MD symptoms for his age, a skewed X-inactivation pattern in the 47, XXY cell line may be suggested.

Keywords

Becker muscular dystrophy (*BMD*); Klinefelter syndrome; paternal non-disjunction; skewed X-inactivation

1. Introduction

Duchenne Muscular Dystrophy, *DMD* (OMIM 310200), is the most common muscular dystrophy in males, observed in approximately 1 in 3-4500 males. This condition leads to the absence or deficiency of the protein dystrophin and causes continued degeneration of muscle fibers. It has an allelic variant, with a milder phenotype, called Becker-type Duchenne Muscular Dystrophy (*BMD*; OMIM 300376) [1, 2].

This progressive and debilitating condition is due to various mutations at the Dystrophin gene (*DMD*) level, located in Xq21 and considered by now the third largest gene in the human genome [3]. Frameshift mutations and large deletions are associated with the most severe phenotypes [2].

For its part, Klinefelter Syndrome (*KS*) is a relatively common disorder in infertile men, resulting from a sexual chromosomal aneuploidy. It is due to an extra X chromosome, which can develop by errors in paternal meiosis I or maternal meiosis I or II [4].

The coexistence of two genetic syndromes in the same person has recently been a more frequently reported event, probably due to greater access to various genetic diagnostic technologies. However, such observation remains rare, and accordingly, considering the presence of two genetic conditions in one patient with an atypical clinic is somewhat unexpected.

We present the case of a man presenting muscular dystrophy resembling Becker phenotype and Klinefelter syndrome. We discuss its clinical phenotype and molecular mechanisms and compare it with some cases in the literature.

2. Clinical Case

The proband was a 35-year-old man and the only child of non-consanguineous parents, being young at conception, with no history of neuromuscular disease in the family.

He was the product of a pregnancy with complications during 1st trimester and a full-term cesarean delivery without neonatal complications. At 9 months, he began to walk, but from 3.5 years onwards, waddling gait and motor clumsiness are noted. At the age of 8 years, weakness appeared in his lower limbs, and he could not climb stairs or run efficiently, making Gowers' sign noticeable. At this age, a muscle biopsy of the left biceps was performed, revealing slight peri fascicular fibrosis with mild focal inflammatory infiltrate and signs of congestion. No signs of atrophy were observed, and the sarcolemma was preserved. Based on these findings, he was diagnosed with mild muscular dystrophy in infancy.

With age, the muscular involvement was more evident since his gait was affected, his stumbles were frequent, and his shoulder and pelvic girdle weakness led him to a wheelchair at the age of 32. Moderate scoliosis is observable with a Cobb Angle of 18 degrees. The CPK analysis reflects values of 4011 IU. In the ECG, the ventricular ejection fraction is 71% with preserved global and segmental contractility, while the respiratory function parameters are the most affected with CVF 2140 (43) and FEV1 1940 (47) compatible with a moderate restriction.

The patient did not offer consent for a new muscle biopsy.

The development of secondary sexual characteristics was delayed, and at 24 years of age, due to notable testicular hypoplasia, a testicular biopsy was performed, and the absence of testicular parenchyma was confirmed, corroborated by azoospermia.

The authors declare that no experiments were performed on humans or animals for this study, and they have followed the protocols of National Registry of Duchenne Dystrophy, on the publication of patient data. The authors obtained the patient's written informed consent, which is mentioned in the article. The corresponding author has this document.

2.1 Banding Cytogenetic Analysis

Karyotyping was performed by culture of peripheral blood lymphocytes according to standard procedures. Chromosome preparations were obtained and analyzed using a GTG banding of twenty metaphases. Karyotyping of the parents was not performed.

2.2 Molecular Genetic Studies

Genomic DNA extraction was done from peripheral blood of the index and his parents and subsequently used for:

2.2.1 Analysis of Deletions and Duplications in the *DMD* Gene

MLPA (Multiplex Ligation dependent Probe Amplification) analyses of the *DMD* gene were done according to the manufacturer's instructions on DNA of the index using the MRC Holland® P034 and P035 probe kits, which analyze all 79 exons (NM_004006.3). Bioinformatic analysis of the data obtained was performed using Coffalyser.net software.

2.2.2 Complete Sequencing of the *DMD* Gene Using Next-Generation Sequencing

Genomic DNA was enriched for target regions using a hybridization-based protocol and sequenced using Illumina technology. Target regions were sequenced at $\geq 50\times$ depth, and reads were aligned to a reference sequence (GRCh37). Enrichment and analysis focused on the coding sequence of the indicated transcripts, 10 bp of the flanking intronic sequence, and other specific genomic regions that have been shown to cause DMD disease. Promoters, untranslated regions, and other noncoding regions were not evaluated. DNA of the patient and his mother was studied.

2.2.3 STR Markers Study

This study used genomic DNA from the index patient and his parents. 10 genes/markers, as shown in Table 1 were applied in Short Tandem Repeat (STR) marker analyses. 1 marker was specific

for X and Y chromosomes, 6 for the X, and 3 for the Y. ST-analyses were done according to Dash et al. [5]. In short, STR markers were amplified using standard PCR protocols. Separation and detection of the amplified fragments were carried out on ABI 3500 Genetic Analyzer (Thermo Scientific, US) using a 50 cm 8-capillary array, POP-7 polymer suitable size standard, and an allelic ladder. Finally, the alleles were designated by Gene Mapper v.5.0 software (Thermo Scientific, US) using data obtained from the size standard, allelic ladder, and the provided beans and panels. Results were compared on a marker-to-marker basis for their concordance and/or discordance.

Table 1 Analysis STR markers for the X-chromosome results.

Gene/marker	Localization	Origin in index
Amelogenin	Xp22/Yp11.2	not informative
DXS6807	Xp22.32	biparental
DXS9898	Xq21.31	biparental
DXS6797	Xq22.3	not informative
DXS7133	Xq22.3	biparental
DXS6854	Xq25	biparental
HPRTB	Xq26	not informative
SRY	Yp11.31	paternal
DYS439	Yp11.2	paternal
DYS392	Yq11.22	paternal

3. Results

Banding cytogenetic analysis revealed a mosaic karyotype $mos\ 47,XXY[32]/46,XY[18]$ (Figure 1).

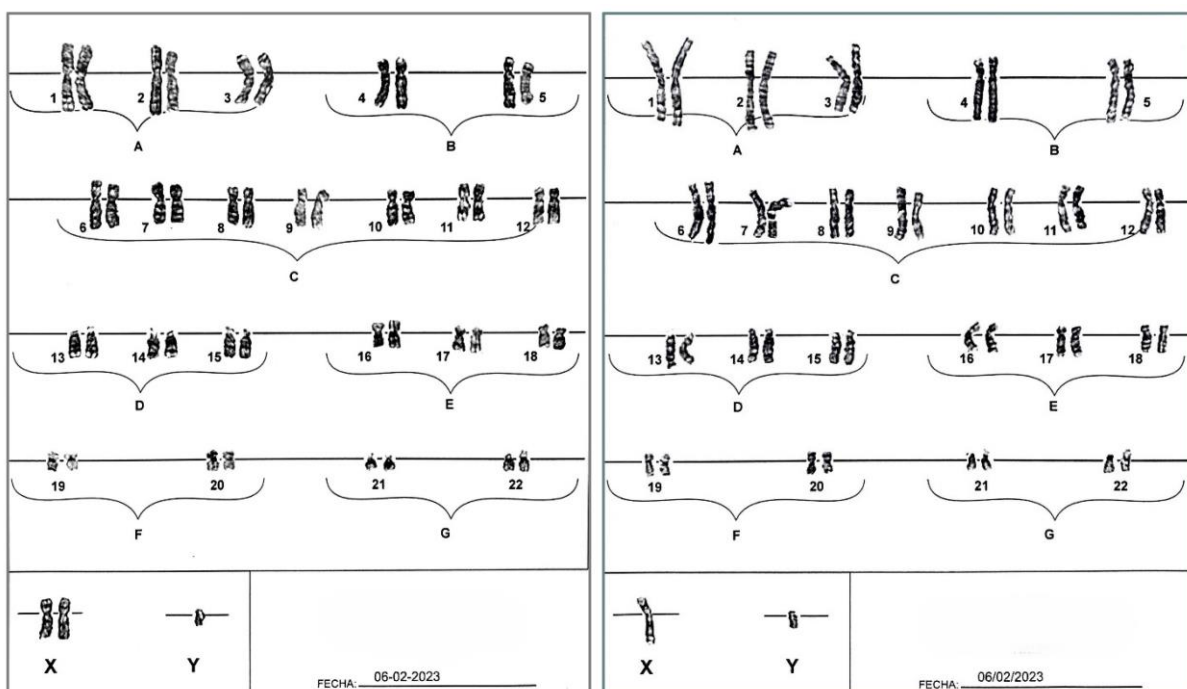


Figure 1 Conventional Karyotype, using G banding, shows $mos\ 47,XXY[32]/46,XY[18]$.

MLPA studies of the patient’s *DMD* gene revealed no deletion or duplication. Next-generation sequencing (NGS) of patient DNA showed a heterozygote variant of uncertain clinical significance c.9091G>T; p.Val3031Phe (missense) in his *DMD* gene. NGS in the mother excluded this mutation, suggesting a causative mutation and *de novo* origin.

STR marker analyses (Table 1) revealed that X-chromosomes were of biparental origin, and Y-chromosome was paternally derived (confirmed parenthood).

4. Discussion

We describe a double genetic condition involving the X chromosome: a numerical aberration of sex chromosomes as XXY and a *DMD/BMD* gene missense variant.

Eight cases have been reported with this clinical duality, most of them with a clear family history of muscular dystrophy. [6] reported a patient with Klinefelter syndrome and BMD in whom the second X chromosome was of paternal origin. The proband phenotype was milder than other affected illnesses in his sibship. [7] describe a patient with Klinefelter syndrome and Becker phenotype explained by a homozygous deletion of the exons 45-47 of the dystrophin gene; interestingly, the clinical course of this patient regarding motor functions is similar to our case. [8] reported a 31-year-old male with karyotype 47, XXY, who had muscle symptoms with left-right differences and intellectual disability. Notably, in most cases described and ours, the mild Becker phenotype has been the first diagnostic suspicion [9, 10]. Three more cases were reported by [11-13].

Non-disjunction has been related to advanced maternal age. However, in the case of Klinefelter syndrome, the paternal origin of the X chromosome, as a consequence of segregation failure in meiosis I, has been reported in up to 50% of the cases (11). Given the proportions of the two cell lines found in our patient, we postulate as a possible mechanism an originally trisomic embryo due to non-disjunction of both paternal sex chromosomes during meiosis I; this was followed by a trisomy rescue event in first postzygotic cells, generating the mosaic 46, XY line (Figure 2).

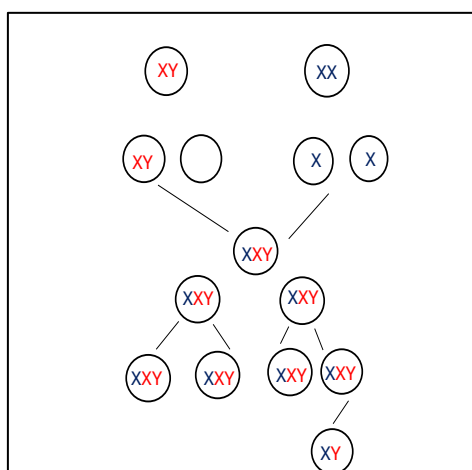


Figure 2 Shows non-disjunction of paternal sex chromosomes in Meiosis I and postzygotic error leading to a mosaic situation.

In the presented patient, a missense variant, c.9091G>T; p.Val3031Phe, was also found in the *DMD/BMD* gene. This variant affects the central rod-associated domain of exon 61 of the protein.

The variant is classified as of unknown importance in many databases consulted, such as Clin var, Varsome, Franklim, Lovd, and Dove. There are no reports of this type of variant in the database of 1000 genomes, which could imply a low population frequency. The multiple prediction models applied for its pathogenicity are discordant (SIFT, PolyPhen, and Provean classify it as probably harmful since it could create a splicing silencing site; however, other predictors consider it neutral.

This variant was not observed in the mother; such a *de novo* event occurs in up to 30% of men with *DMD*. It should be noted that in three of the eight previous cases with these two coincident pathologies, the attenuated form of expression of muscular dystrophy in families with clear inheritance of this condition constituted an index of suspicion for the search of some other genetic mechanism that would support this observation [11-13].

A significant clinical aspect in our patient is the presence of a less severe muscular phenotype, which agrees with what is expected for his karyotypic constitution. Having the *DMD/BMD*-gene VUS in heterozygosity due to the presence of two X chromosomes with non-random patterns of inactivation, a clinical behavior should be expected regarding *DMD/BMD*, similar to that observed in female carriers of this condition, where muscle involvement is usually discreet. Another possible explanation to support the observed *BMD* phenotype in the patient is either a skewed X inactivation pattern that reduces the severity and/or that the X-chromosome lost in 30% of the cells in the blood (which needs not to be representative for the whole body) is the one without the mutation.

X chromosome inactivation in XXY males has been little studied. However, some reports indicate more or less random patterns in most cases. However, there also are rare exceptions with severely skewed inactivation [14, 15].

Some limitations of the study of this case have been the non-performance of an exonic NGS to rule out autosomal recessive muscular dystrophies except for Pompe Myopathy, which was ruled out, and the absence of functional studies that support a potentially harmful effect of the variant. *DMD* nonsense, in dystrophin mRNA and protein.

5. Conclusion

The association of Becker phenotype *MD* and Klinefelter syndrome is quite rare. Here, we add the ninth case to the literature. Clinical signs of both conditions can be present, but muscular impairment may be less severe, probably due to the X inactivation phenomenon, so such patients resemble *BMD*.

Acknowledgments

We want to thank the entire work team of the Genetics Service of the Specialty Hospital No. 1 of the Armed Forces in Quito-Ecuador, for the laboratory test and PTC therapeutics S.A, who supports the molecular studies.

Author Contributions

The contributions of the authors are represented according with: A. Conception and design of experiments. B. Acquisition and analysis of data. C. Writing and revising the manuscript. D. Others (specify). Arianne Llamas Paneque: A, B, C. Isabel Echevarría Frutos: B, C. Amaury León Sosa: B, C. Thomas Liehr: C, D (Molecular studies). Tanja Herrmann: D (Molecular studies).

Funding

This research received no funding or grant.

Competing Interests

The authors have declared that there are no conflicts of interest.

References

1. Mohamed K, Appleton R, Nicolaides P. Delayed diagnosis of Duchenne muscular dystrophy. *Eur J Paediatr Neurol.* 2000; 4: 219-223.
2. Suthar R, Sankhyan N. Duchenne muscular dystrophy: A practice update. *Indian J Pediatr.* 2018; 85: 276-281.
3. Megía González R. The guinness records of the human genome [Internet]. Genotipia; 2021. Available from: <https://genotipia.com/record-guinness-del-genoma-humano/>.
4. Butler G, Srirangalingam U, Faithfull J, Sangster P, Senniappan S, Mitchell R. Klinefelter syndrome: Going beyond the diagnosis. *Arch Dis Child.* 2023; 108: 166-171.
5. Dash HR, Rawat N, Vajpayee K, Shrivastava P, Das S. Useful autosomal STR marker sets for forensic and paternity applications in the Central Indian population. *Ann Hum Biol.* 2021; 48: 37-48.
6. Suthers GK, Manson JI, Stern LM, Haan EA, Mulley JC. Becker muscular dystrophy (BMD) and Klinefelter's syndrome: A possible cause of variable expression of BMD within a pedigree. *J Med Genet.* 1989; 26: 251-254.
7. Zeitoun O, Ketelsen UP, Wolff G, Müller CR, Korinthenberg R. Rare combination of Becker muscular dystrophy and Klinefelter's syndrome in one patient. *Brain Dev.* 1997; 19: 359-361.
8. Takizawa H, Mori-Yoshimura M, Minami N, Murakami N, Yatabe K, Taira K, et al. A symptomatic male carrier of Duchenne muscular dystrophy with Klinefelter's syndrome mimicking Becker muscular dystrophy. *Neuromuscul Disord.* 2021; 31: 666-672.
9. Xu M, Fang F, Xu J. Rare combination of dystrophinopathy and Klinefelter's syndrome in one patient. *Chin J Pediatr.* 2014; 52: 548-551.
10. Hennekam RC, Veenema H, Bakker E, Jennekens FG, Te Velde ER, de Pater J. A male carrier for Duchenne muscular dystrophy. *Am J Hum Genet.* 1989; 44: 591-592.
11. Nagaoka SI, Hassold TJ, Hunt PA. Human aneuploidy: Mechanisms and new insights into an age-old problem. *Nat Rev Genet.* 2012; 13: 493-504.
12. Ramesh V, Mountford R, Kingston HM, Kelsey A, Noronha MJ, Clarke MA. Occurrence of Duchenne dystrophy in Klinefelter's syndrome. *Arch Dis Child.* 1993; 69: 453-454.
13. Santoro L, Pastore L, Ripa PG, Orsini AV, Del Giudice E, Vita G, et al. Dystrophinopathy in a young boy with Klinefelter's syndrome. *Muscle Nerve.* 1998; 21: 792-795.
14. Viggiano E, Picillo E, Ergoli M, Cirillo A, Del Gaudio S, Politano L. Skewed X-chromosome inactivation plays a crucial role in the onset of symptoms in carriers of Becker muscular dystrophy. *J Gene Med.* 2017; 19: e2952.
15. Kinjo K, Yoshida T, Kobori Y, Okada H, Suzuki E, Ogata T, et al. Random X chromosome inactivation in patients with Klinefelter syndrome. *Mol Cell Pediatr.* 2020; 7: 1.