

Review

## Disturbed Ovarian Differentiation in XX;SRY-Negative Dogs

Rita Payan-Carreira \*

Departamento de Medicina Veterinária, ICAAM-Instituto de Ciências Agrárias e Ambientais Mediterrânicas, Escola de Ciências e Tecnologia, Universidade de Évora, 7006-554 Évora, Portugal;  
E-Mail: [rtpayan@gmail.com](mailto:rtpayan@gmail.com)

\* **Correspondence:** Rita Payan-Carreira; E-Mail: [rtpayan@uevora.pt](mailto:rtpayan@uevora.pt)

**Academic Editor:** Sergei G. Tevosian

**Special Issue:** [Ovarian Development and Differentiation](#)

*OBM Genetics*

2019, volume 3, issue 2

doi:10.21926/obm.genet.1902074

**Received:** December 30, 2018

**Accepted:** April 19, 2019

**Published:** April 29, 2019

### Abstract

In a mammal, at the beginning of its development, the gonad is bipotential. The shift into a male or female pathway is coordinated by the sex chromosomal complement, which triggers a series of genetic pathways signaling the developmental pattern of the gonadal anlage. Being mutually exclusive, the differentiated gonad should be either a testis or an ovary. In females, the absence of SRY, a testis-determining gene, drives the signaling cascades controlling the ovarian differentiation. Albeit rare, disorders of the gonadal differentiation may occur in men and domestic animals and may cause infertility or sterility. In dogs, the XX;SRY-negative disorder of sexual development (DSD) is the most frequent condition. The disorder typically presents a wide spectrum of developmental conditions of the gonad and variable virilization of the genital phenotype, that may be accompanied by hypospadias. This condition may be inherited as a sex-limited autosomal recessive trait; however, the mechanism explaining its occurrence remains poorly understood. This review intends to present an overview of the morphologic features of XX;SRY-negative syndrome in dogs, while addressing the current knowledge regarding the genetic mechanism underlying this condition.



© 2019 by the author. This is an open access article distributed under the conditions of the [Creative Commons by Attribution License](#), which permits unrestricted use, distribution, and reproduction in any medium or format, provided the original work is correctly cited.

## Keywords

Disorders of sexual development; intersex; sex reversal; gonadal differentiation; ovotestis; hypospadias; dogs

## 1. The XX;SRY-Negative DSD Condition in Dogs

Even though Disorders of Sex Development (DSD) are rare genetic conditions in dogs, the most common in occurrence is the testicular (T-DSD) or ovotesticular (OT-DSD) disorder, presenting a female karyotype and a lack of the SRY (sex-determining region Y) gene (78,XX;SRY-negative DSD) [1]. Dogs are the domestic species presenting the XX female-to-male sex reversal condition most [2], with sporadic descriptions appearing in horses [3, 4], cats [5] and pigs [6].

In an older nomenclature, this condition was categorized as intersex, under the XX true hermaphroditism or the XX sex reversal (or XX male syndrome) conditions [7]. This disorder is characterized by a wide spectrum of developmental conditions of the gonad, co-existing with variable virilization of the genital phenotype [8, 9]. The higher prevalence of XX;SRY-negative DSD in particular breeds (e.g., the English and the American Cocker Spaniel, the Beagle or the Pug) and genetic lines [7, 10, 11], sustains the hypothesis that this condition may be inherited as a sex-limited autosomal recessive trait [1, 8].

In normal dogs, as in other placental mammals, the sexual development comprises three sequential steps; namely the definition of the sex chromosome complement at fertilization, the differentiation of the gonads as testis or ovary (gonadal sex), and the differentiation of the tubular and phenotypic sex, determined from the gonadal sex [2]. In males, testis differentiation is triggered by the expression of SRY that generates a cascade of molecular events that coordinate the differentiation of the urogenital tract into a male pattern. In the female embryo, differentiation proceeds in the absence of SRY expression, leading to the activation of a non-masculinizing cascade of events directing the development of the embryo reproductive tract according to the female pattern [12]. In mammals, in the normal reproductive tract differentiation, male and female patterns are mutually exclusive.

The process of sexual differentiation is rather complex and so finely tuned that a minimal alteration, whether in the activation of the genes involved in the gonadal sex differentiation or in the functioning of downstream molecular pathways, may originate severe DSD disorders. This review focuses on the morphological characterization of the XX;SRY-negative syndrome in dogs and addresses the current state of understanding of the genetic mechanism underlying this condition.

### 1.1 The Phenotype of XX;SRY-Negative Dogs

The phenotype of naturally occurring conditions in dogs remarkably resembles that of the XX DSD ovotesticular or testicular subtype in humans [13]. Affected dogs may present either ovotestis or testicles [14]. Table 1 summarizes the information gathered from available publications on XX;SRY-negative conditions in dogs whose diagnoses were supported by the karyotype and cytogenetic analyses establishing the absence of SRY. Even though in most cases a female

phenotype prevailed, with animals showing an enlarged clitoris with internal baculum exposed from the vulva, on what concerns the gonad development the prevalent morphology was the testicular (Table 1).

Albeit most affected dogs present either bilateral testes or ovotestis [8], a combination of a testicular gonad on one side and an ovotestis in the other may sporadically be found (Table 1). This seems to contrast the report by Meyers-Wallen, that describes a smaller prevalence of bilateral testis in American Cocker dogs suffering from XX-DSD. Due to the small number of cases diagnosed within each breed, testing to discern if these differences could be explained by the genetic background of the individuals is not allowed.

In both the testicular and the ovotesticular sub-types, the gonads are generally found in an intra-abdominal position, and animals are diagnosed as cryptorchid. Since some development of the Wolffian derivatives occur, the epididymides are found, as well as a partially underdeveloped vas deferens, which runs parallel to the walls of a hypoplastic uterus [8, 31]. These animals usually present Wolffian duct derivatives, like the epididymides, and a more or less rudimentary vas deferens [8, 15, 17, 23], along with persistence of a uterus. Albeit the existence of a prostate has been described in some cases [32, 33], in my professional practice the prostate was never located by digital palpation, visualized during surgery, nor reported by any other authors [8, 16].

In general, ovotestis in 78,XX;SRY-negative dogs are involved by the ovarian bursa (Figure 1A), like the ovaries in normally developed females [31]. Although small fragments of ovarian tissue containing a few, sporadic follicles often showing degenerative changes may be found in cortical position (Figure 2), the ovarian differentiation is usually compromised. Also, these small patches of ovarian tissue are limited to some areas of the gonadal cortex, for which multiple non-continuous sections of the gonad are needed to establish a sound histological diagnosis of ovotestis. In some cases, the existence of antral follicles or corpora lutea have been described [22], as well as the existence of ovarian cycles [8, 23]. However, according to available reports, most XX;SRY-negative dogs never experienced estrus [9, 25].

The testicular pattern is not entirely obtained either. Albeit formation of testicular lobules occurs, usually the mediastinum testis is not found in these animals (Figure 1B), whether in ovotestis or in testicle-like gonads, which may make it difficult to discern the abdominal location of the gonad during an ultrasonographic examination [31]. XX;SRY-negative dogs frequently present both oviducts and epididymis (Figure 1), mainly when ovotestis are present; all animals present an underdeveloped uterus. Often, a rudimentary or hypoplastic vas deferens can be seen running parallel or inserted in the wall of uterine horns [8, 31].

**Table 1** Reported cases of 78,XX;SRY-negative dogs supported by karyotype and cytogenetic analysis.

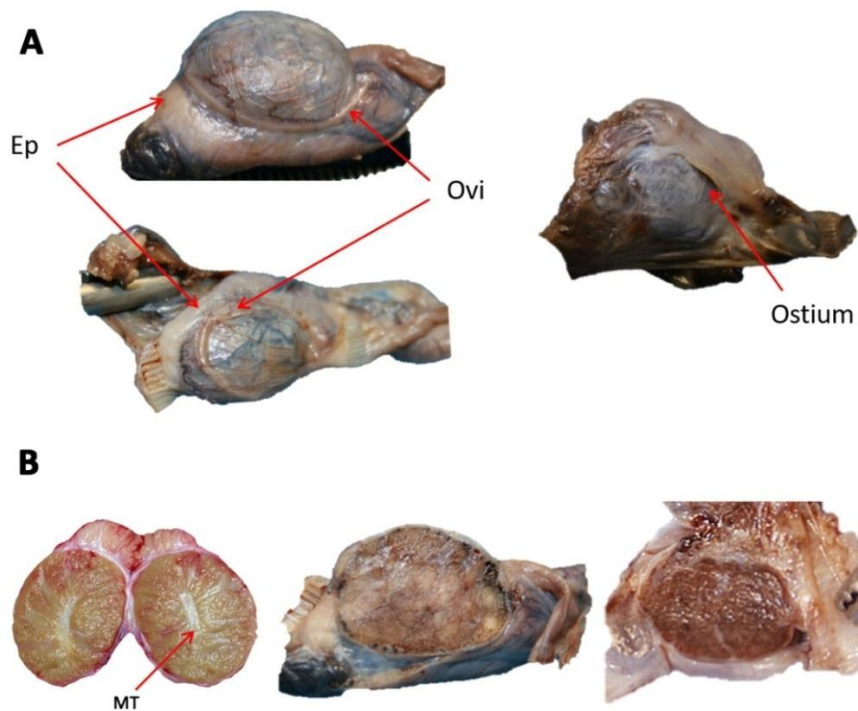
Phenotype scored at birth	n	Breed	Type of gonads [Test/Ovot/Ov]	Position [ABD/ING/SCr]	External morphology	Internal morphology	Comments	References
Male	1	French Bulldog	Bilateral Test	ABD	Hypoplastic penis Preputium caudally dislocated Cryptorchidism Absent scrotum	Epididymides Oviducts not found Uterus	-	[15]
Male	1	Pug	Bilateral Test	SC-ING [left] ABD [right]	Hypoplastic penis Preputium caudally dislocated Cryptorchidism Absent scrotum	Uterus	-	[16]
Female	1	French Bulldog	Bilateral Test	ING	Vulva in ventral position Enlarged clitoris with bone	Atresia of the cranial vagina No other information	-	[17]
Female	1	Jack Russell Terrier	Bilateral Test	ABD	Vulva Enlarged clitoris with bone Increased anogenital distance compared to normal females	Uterus No other information	-	[18]
Female	1	English Cocker Spaniel	Bilateral Test	ABD	Vulva; Enlarged clitoris with bone	Epididymides not found Uterus	-	[19]
Female	1	Beagle	Bilateral Test	ABD	Vulva; Enlarged clitoris with bone	Uterus Epididymides or vas deferens not found	Dysuria Androgen levels under reference range for male dogs	[20]

Female	1	American Staffordshire Terrier	Bilateral Test	ABD	Vulva; Enlarged clitoris with bone	Small uterus	-	[21]
Female	1	Whoodle	Ovot [previous unilateral gonadectomy]	ABD	Vulva	Gonad with CL	Estrus behavior and enlarged mammary glands Increased blood progesterone	[22]
Female	2	Cocker Spaniel [English]	Bilateral Ovot	ABD	Vulva; Enlarged clitoris with bone	Ovarian bursa Oviducts Epididymides and vas deferens Uterus	Anestrus Male-like behavior	[23]
		PitBull cross					Anestrus Occasional male attraction, mammary hypertrophy and milk ejection Increased blood progesterone	
Female	2	Norwegian Elkhounds	Bilateral Ovot	ABD	Vulva; Enlarged clitoris with bone	Uterus and vagina Epididymides and vas deferens not found		[24]
			Bilateral Test	ABD		Uterus and vagina Epididymides and vas deferens		
Female	1	Basset Hound	Bilateral Ovot	ABD	Vulva; Enlarged clitoris with bone	Oviducts Epididymides Uterus Shortened vagina	Mucopurulent vaginal discharge	[25]

Male	2	English Cocker Spaniel	Test + Ovot	ABD	Hypoplastic penis Preputium caudally dislocated Penile hypospadias Absence of scrotum Bilateral cryptorchidism	Unilateral ovarian bursa [Ovot] Epididymis [Test] Uterus	-	[9]
Female			Bilateral Ovot		Vulva Enlarged clitoris with bone No scrotum	Ovarian bursa Oviducts Rudimentary epididymides and vas deferens Uterus		
Female	2	Pitbull Beagle	Bilateral Test	ABD	Vulva Enlarged clitoris with bone	Epididymis Uterus	-	[26]
Female	1	Mongrel	Bilateral Test	ABD	Vulva Enlarged clitoris with bone	Oviducts not found Rudimentary epididymides Uterus	Testosterone levels within normal range for male dogs	[27]
Female	5	Basset Hound Soft coated Wheaten terrier	Bilateral Ovot	ABD	Vulva Enlarged clitoris with bone	Not provided	-	[28]
		Beagle Walker Hound	Bilateral Test					
		Doberman	Ov + Ovot					
Not mentioned	12	American Staffordshire Terrier [2] Pug [1] Cocker spaniel	Bilateral Test	ABD	Not provided	Not provided	-	[29]

		[English] [1] French Bulldog [2]					
		Leonberg [1] Cocker Spaniel [English] [2] Beagle [1]	Bilateral Ovot				
		Bernaise Mountain dog [1]	Ovot+Test				
		French Bulldog [1]	Test +neoplastic gonad				
Not mentioned	4	Cocker spaniel [English] American Staffordshire Terrier	Bilateral Test	ABD	Not provided	Not provided	-
		Beagle Cane Corso	Bilateral Ovot				[30]

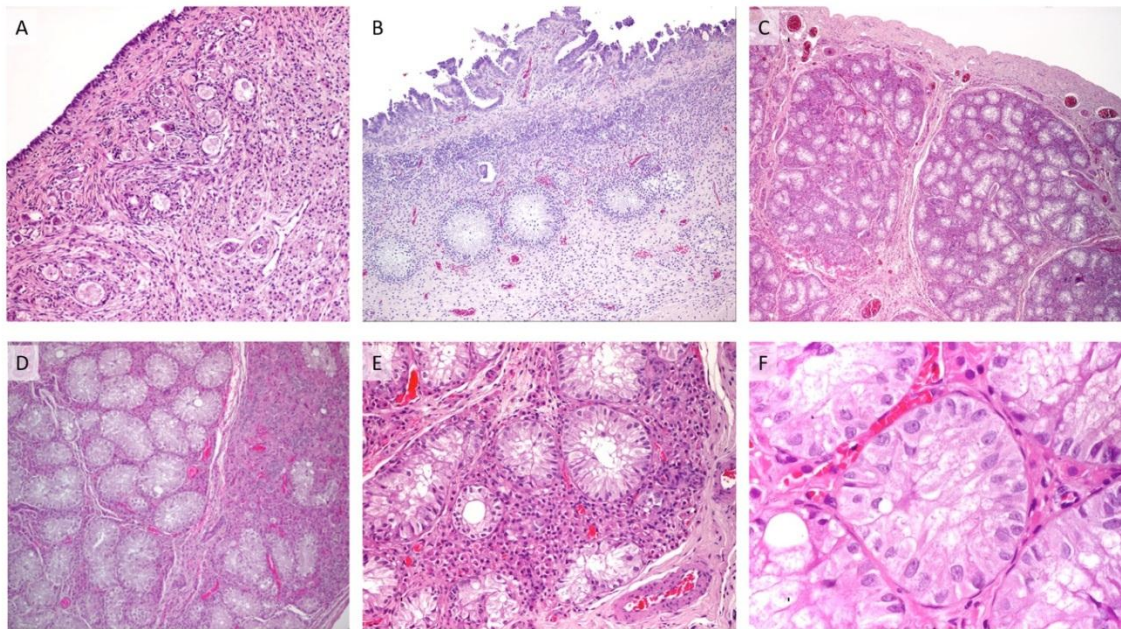
Ovot-ovotestis; Test-testicle(s); Ov-ovary; ABD-abdominal; ING-inguinal; SCr-scrotal; SC-subcutaneous



**Figure 1** The morphology of the gonad in XX;SRY-negative dogs resembles that of a male (ovoid, compact structure) in intra-abdominal location. **A.** The gonad is often located within the ovarian bursa, which supports the oviduct (Ovi); the epididymis (Ep) usually runs parallel to the gonad. The ostium of the ovarian bursa may be found on the medial face. **B.** The mediastinum testis (MT) usually found in the centre of the longitudinal sections of a normal testicle (on the left) is not perceived in the XX;SRY-negative gonad (at the middle and right in the bottom image).

Histological analysis of the gonads usually reveals a predominance of testis-like structures. Sertoli cells-only seminiferous tubules are often found, but sporadic degenerative spermatogonia and rare leptotene may also be observed [9]. However, the absence of germ cell stratification is the rule. In the interstitium, it is often observed an increase in the density Leydig cells [9], which often show a more eosinophilic cytoplasm, suggesting its immaturity. Similar features are found in Leydig cells in intra-abdominal cryptorchid testis in dogs (Payan-Carreira, unpublished). This parenchyma represents the totality of the gonad in the testicular type of gonads, or occupies a large medullary zone of the gonadal tissue, in the case of ovotestis. In either the ovotestis or testicular sub-type of XX;SRY-negative gonads, irregular lobulation may be found (Figure 2), originating from bundles of connective tissue that originate from the albuginea [31], a dense capsule of connective tissue delimiting the testis. If an ovotestis exists, the continuity of the albuginea is interrupted by the presence of an epithelial layer similar to the surface epithelium found in the dog ovary (Figure 2). Under the area of the surface epithelium, follicles in different stages, some displaying signs of atresia, may be evidenced in cortical position [7, 8]. Most frequently, they are primordial and primary follicles but, in some cases, they might reach the antral stage and be endocrinally active. Nonetheless, the density of the follicles in the cortical stroma is lower than the usual for the normal ovary (Payan-Carreira, unpublished), and therefore the connective tissue predominates.

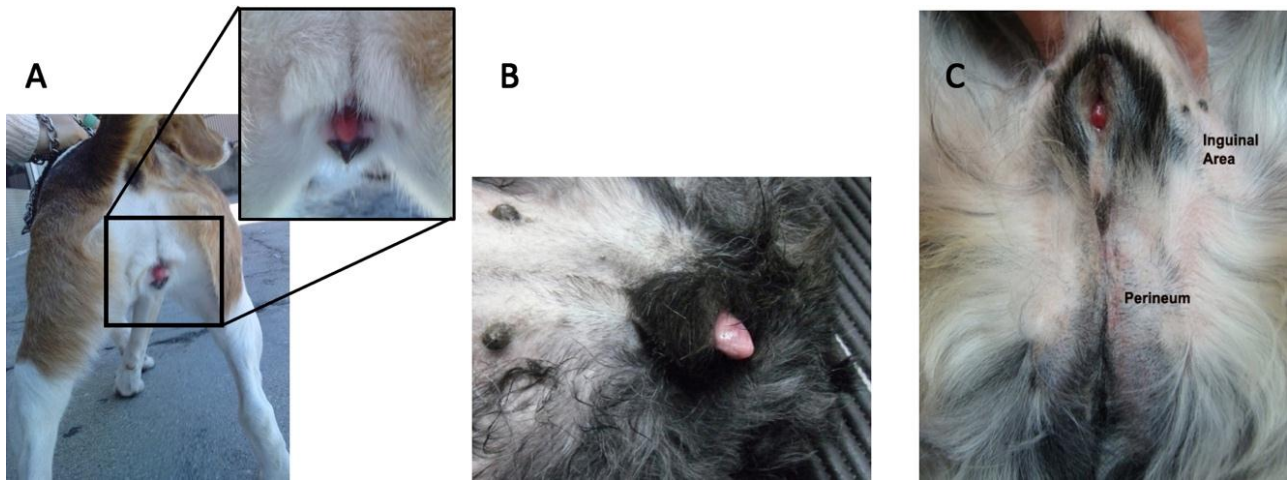




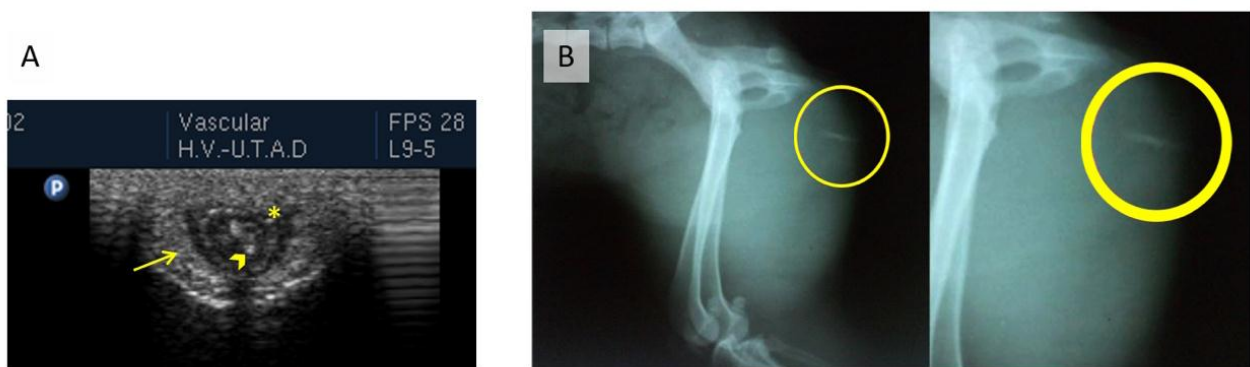
**Figure 2** Microscopic images of XX;SRY-negative gonads (hematoxylin-eosin staining). In the ovotesticular sub-type, scant follicles are found scattered in the cortex presenting a dense ovarian-like stroma. **A** Germ cells are surrounded by a single layer of flat or cuboid granulosa cells (100x). **B**. In the areas presenting follicles, the existence of a structure resembling the surface epithelia may be found (200x). **C**. In smaller magnification the existence of testicular lobules may be perceived, the septa originating from the dense albuginea cover typical of the testis (40x). **D**. Some disorganization may also be found among the gonadal lobules, with some of the lobules presenting a small number of seminiferous tubules and a predominance of interstitial elements (200x). **E**. In general, large eosinophilic Leydig cells are observed in testicular or ovotesticular DSD gonads (200x). **F**. The seminiferous tubules comprise mainly Sertoli cells and often are devoid of germinal epithelium; the lumen is also often absent (400x).

In general, XX;SRY-negative dogs are bilateral cryptorchid, and their phenotype displays a variable degree of masculinization. Most commonly, dogs present a vulva and a hyperplastic clitoris (Figure 3) although they might also present a rudimentary penis within a shortened preputium (Figure 3) [31], opening closer to the anus [8, 31] and hypospadias (urethra opening in the underside of the penis). The examination of the enlarged clitoris reveals the existence of an undeveloped baculum, whose existence may be confirmed by ultrasound scanning and X-rays in lateral recumbency (Figure 4).

In either case, the scrotum is usually absent, and the gonads are in an intra-abdominal location. In the transrectal evaluation, the prostate is generally absent whether in animals with a female or a male phenotype [31]. Meyers-Wallen [8] mentions that in the American Cocker, the phenotype of a vulva with a protruding clitoris is observed in 15% of the cases; but in other breeds, that phenotype seems to be described more frequently than the more masculinized one, where a short prepuce and penis are present (Table 1; Figure 3).

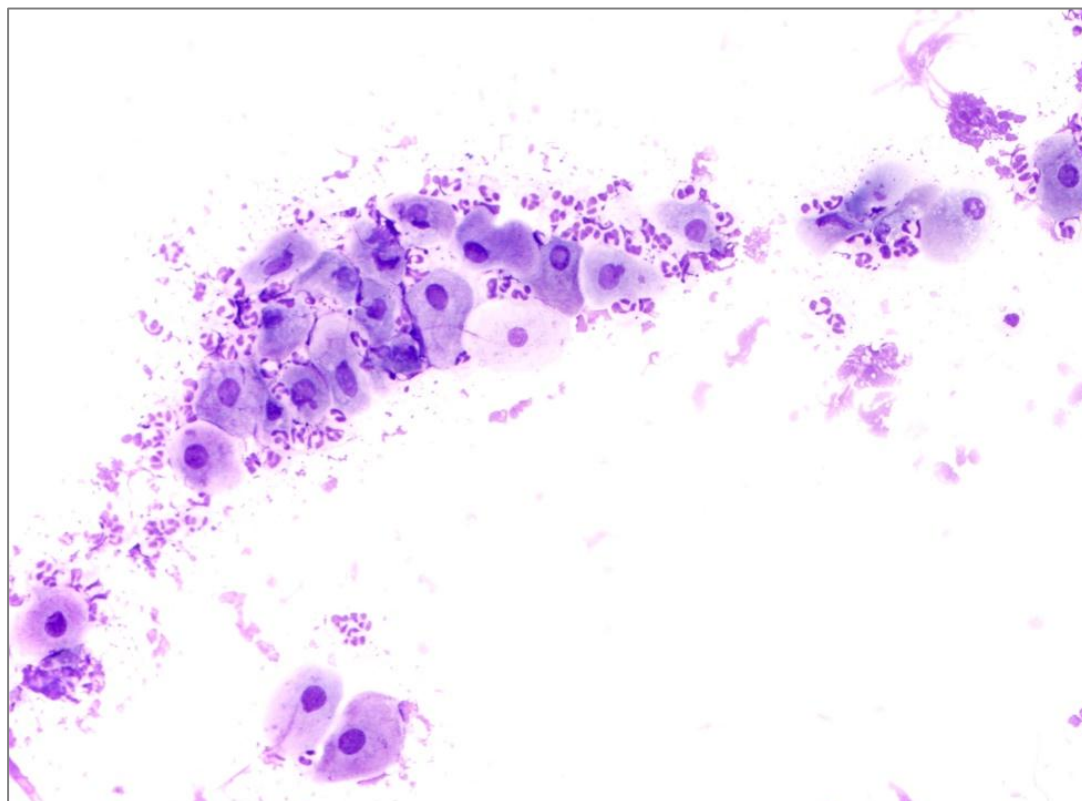


**Figure 3** The external genitalia of XX;SRY-negative dogs may show two main patterns: a female type (A and B) with a vulva placed in ventral position and an enlarged clitoris exposed from the vulva; and a more virilized, male-like type (C), showing a prepuce, usually shorter than in normal males, but without development of the scrotum. The animal is usually a bilateral cryptorchid.



**Figure 4 (A)** The ultrasound examination of the vulvar area shows the presence of a residual baculum (▶) within a structure resembling a rudimentary penis (\*), surrounded by thick skin folders (arrow). **(B)** On the X-ray, the presence of the baculum can also be perceived (within the yellow circle).

In dogs presenting a male-like phenotype, the ostium of the prepuce does not display its usual appearance, but rather resembles the vulvar folders of females (Figure 3C), with the preputial ostium in an eccentric position. Nonetheless, in dogs with a female phenotype, the vagina terminates shortly in a cul-de-sac. The exploitation of the short sized vaginal cavity is often difficult. A vaginal cytology can be obtained. It is useful to confirm the inability to progress the swab through the vaginal vault, and typically presents the features of a male preputial cytology (Figure 5).



**Figure 5** Vaginal cytology from a XX;SRY-negative dog with a female like phenotype, showing the presence of a large round epithelial cells and a considerable number of neutrophils (Diff-Quick® staining; 200x).

## **2. A Short Overview of the Gonadal Differentiation in Embryos**

### **2.1. The Determination of the Normal Gonadal Pattern**

Precursor cells of gonads originate from the urogenital ridges, which are morphologically identical in XX and XY embryos [34]. First, a bipotential gonad is formed, congregating cells of mesodermal origin, which will be permeated by primordial germ cells. The differentiation of the different gonadal cell lineages (supporting and steroidogenic cells, and peritubular and stromal cells) during the differentiation of the bipotential gonad towards a male or female fate does not need the presence of germ cells [35].

The establishment of a gonadal gender takes place from the same bipotential gonad, depending on the pathway that is activated from the genetic background of the embryo, which is determined at fertilization [36]: 78,XY for male dogs and 78,XX for female dogs. The differentiation of the bipotential gonad towards of the male pathway occurs earlier than the differentiation of the ovary, which was thought to be the default pathway. The differentiation and development of the sexual duct system and the phenotypic sex is subsequent to the establishment of the gonadal sex, and commanded by the gender of the differentiated gonad [36, 37], as it is directed by hormones produced by the differentiated gonad through distinctive local signaling pathways.

Testicular differentiation starts after the entrance of the primordial germ cells in the gonads, and it is coordinated by one cell type [38]. The transition from the undifferentiated rudiment into a male or female gonad is determined by the expression of SRY, a sex determining gene located in

the Y-chromosome [39, 40]. It has been proposed that several genes are required for the development of the bipotential gonad, such as NR5A1, WT1, GATA4 and FOG2, and may be involved in SRY transcription [41]. SRY transcription is limited in time and space [38, 39, 42], but it presents multiple and prolonged effects during the differentiation of the male gonad due to the activation of multilayered downstream pathways. SRY expression begins in the centre of the gonad, spreading towards the pole in a wave, paracrine fashion [34, 43, 44]. Of note, in the bipotential gonad, both the male and female determining genes are expressed at similar levels [40]. These genes are up-or down-regulated during the gonadal differentiation as an answer to the signaling of gender-driven genes. This is an important aspect to retain, as it would explain most features of dysplastic gonads in DSD conditions.

The most important gene activated by SRY is SOX9. This gene is necessary and sufficient to induce testicular differentiation [39, 45]. SOX9 is necessary for the differentiation of Sertoli cells from precursor mesonephric cells, and for the maintenance of the differentiated phenotype, as well as for directing the development of the other somatic testicular cell lineages [12, 39, 40, 42, 46]. Therefore, Sertoli cells act as organizing centers for the diverse morphological transformations that culminate with the formation of testicles [38, 44]. After an initial up-regulation in SOX9 expression, SOX9 is maintained at high levels in Sertoli cells by FGF9 (Fibroblast growth factor gene) signaling, in a feed-forward loop [35] that no longer requires SRY expression [38]. NR5A1 [or SF1, Steroidogenic Factor-1], which along with WT1 (Wilms tumor 1) plays a crucial role in the formation of the bipotential gonad, also acts as a SRY-mediated SOX9 enhancer through testis differentiation [35, 47]. In some species, like in mice, humans, and dogs, a testis-specific enhancer motif (termed Tesco, RevSex and CanRevSex, respectively) has been demonstrated to mediate SRY and Nr5a1 synergic interaction [48] to enhance the transactivation of SOX9 by multiple folds [41]. Additional contributions of other genes from the SOX family [e.g., SOX3 and SOX10] has also been evidenced [41, 49] from the study of DSD conditions.

Acting through its receptor (FGFR2), Fgf9 suppresses the Wnt4 signaling pathway, inhibiting the mechanism that controls the ovarian differentiation [40, 44, 45, 50]. Moreover, Fgf9 sustains SOX9 expression through a positive feedback loop [34]. It is also associated with the testis cord formation, which depends primarily on the Sertoli-Sertoli cell interaction, and is not driven by germ cells [34]. Fgf9 also suppresses meiosis in primordial germ cells, by impairing the rise in retinoic acid in the differentiating male gonads [51]. Cord formation is closely followed by the development of a vascular network from migrating endothelial cells, following a male-type pattern [34, 52] where the more prominent vessels locate at the periphery of the gonad, emitting small branches between the testis cords [53], as well as by the formation of the testicular albuginea [34].

Among other environmental autonomous gonadal signals, prostaglandin D2 promotes SOX9 expression in neighboring cells, thereby being able to recruit somatic precursors cells to the Sertoli cell fate, even in the absence of SRY [40, 44]. This fact may represent an amplification mechanism aiming to ensure the minimum threshold number of differentiated Sertoli cells needed for testicular development [40] since SOX9 expression stimulates Pgd2 levels in the differentiating gonad [34].

The ovary differentiation occurs sometime after the moment of male gonadal differentiation [40], albeit the female-specific genes are transcribed earlier [54]. For long considered as a default process, its mechanism remains less clear than that of the embryonic testicular differentiation. Downregulation of genes associated with the male pathway in XX gonads is crucial to the

commitment to the female fate [49]. In the absence of SRY gene, and consequently in the absence of SOX9 signaling, the canonical WNT signaling pathways are activated in the somatic cell of the gonads [44], a critical step in the ovary differentiation. In response to Wnt4, the vascularization of the gonad takes a typical female pattern, and the somatic cells differentiate as granulosa and stromal cells.

WNT4 (Wingless-type MMTV integration site 4) requires several co-activators to prompt the ovarian differentiation, the RSPO1 (R-spondin ligand 1) representing an important molecule of the canonical Wnt signaling cascade [35, 45]. The activation of the Wnt4 signaling cascade leads to the accumulation of  $\beta$ -catenin, which becomes available to translocate to the nucleus and trigger diverse transcriptional factors [50]. The stabilization of  $\beta$ -catenin exerts a positive feedback over WNT4 expression, with RSPO1 serving as a cofactor. All three genes cooperate to support the gonadal differentiation towards an ovarian fate. In female embryos, activation of the WNT4 gene is accompanied by the expression of RSPO1. The precursors of somatic cells respond to an increase in Rspo1/Wnt4 signaling by accumulating  $\beta$ -catenin [37, 40, 50] and down-regulating SOX9 expression [55]. Loss of function studies in female mice embryos showed the development of a rounded male-like gonad, containing androgen-producing cells and the loss of female germ cells. It has been shown that Wnt4 promotes germ cell survival [50]. Wnt4/Rspo1/ $\beta$ -catenin pathway also regulates the prolonged proliferation of the cortical region, originating the constant recruitment of granulosa cell precursors [56]. Furthermore, Wnt4 and Rspo1 are required to maintain the precursors of the granulosa cells in an undifferentiated status until birth [47].

It has been proposed that the loss of another determining ovarian differentiation gene—FOXL2 (Forkhead Box L2) [37, 45]—may originate an up-regulation of the pro-testis pathway mediated by SOX9 [57], and the transdifferentiation of granulosa cells into Sertoli cells in the adult mouse ovary [58]. The FOXL2 pathway, however, seems to be independent of the WNT signaling cascade, albeit with the same aim—orchestrate the ovary differentiation. Foxl2 is crucial for granulosa cell differentiation and the maintenance of an ovary structure [53]. Stabilization of the granulosa cell differentiation, and therefore of the ovarian differentiation, is further promoted by germ cell commitment to meiosis [49], which in turn is driven by the expression of STRA8, whose expression is dependent of retinoic acid [56, 59].

Since the response to the loss of Foxl2 signaling seems to vary between species, and also with the moment of occurrence, it has been suggested that it may be more important for the maintenance of the female gonad structure than to its differentiation from the bipotential gonad [35, 60]. Disturbed expression of Foxl2 has been associated with ovarian dysgenesis, blockage of follicle formation and disruption of follicle activation in human and mice, besides the ovary-to-testis sex reversal in some species such as goats [45, 50, 57]. Species differences regarding the moment of gonadal female-to-male sex reversal may relate to the physiologic ability for estrogen secretion by the fetal gonads. Therefore, the loss of the ovarian identity in mice occurs in the postnatal ovary, while in polled DSD goats it is established in the fetal gonads [60]. Estrogen up-regulate FOXL2 expression [61]. The loss of FOXL2 function leads to the loss of aromatase expression and the inability to secrete estrogen, along with an up-regulation of SOX9 transcription and subsequent differentiation of Sertoli cells and AMH (Anti-Müllerian Hormone) expression [61]. From the above mentioned it could be suggested that estrogen acts as part of the environmental factors shaping the fate of the developing gonad into an ovary in synergy with FOXL2.

## **2.2. What Might Go Wrong in the Ovarian Development in 78,XX;SRY-Negative Dogs**

In the bipotential gonad, both the male-determining genes (SOX9 and FGF9, for the testis fate, and WNT4 and RSPO1, for the ovary fate) are expressed at similar levels [40, 45]. At the moment of gonadal differentiation, SOX9 expression is raised in male embryos, but maintained in residual levels in females [45]. Since the precursor cell types are similar in the bipotential gonads of both female and male embryos [43], once the fate of the supporting cells is established, it orchestrates the differentiation of all other cell lineages in the gonad [49].

Considering that the ovarian-determining pathway actively suppresses the testis-determining pathway [38], one could suspect that, in the case of female-to-male sex reversal, a disruption of the female-determining genes would occur, which in turn would allow the activation of the male-determining genes, even in the absence of SRY transcription. In some species, it has been demonstrated that the loss of function of *Rspo1*, *Foxl2* and estrogen receptor alpha will activate the male-determining pathway, upregulating SOX9 [38]. It has also been shown that in the absence of *Wnt4*, the transcription of FGF9 is upregulated [38].

The multi-layered input into sex determination [40], with multiple signaling cascades determining the fate of the embryonic gonad between the male and a female pattern, makes it difficult to identify the mechanism underlying the XX;SRY-negative syndrome, as well as the range of abnormalities described in the gonads of affected animals. The commitment of the precursor somatic cells of bipotential gonads toward a male or female fate drives the gonadal differentiation in the fetus [41]. The differentiation of Sertoli cells early in the process will, therefore, constrain the pattern of the differentiating gonad.

The development of a gonad into a testicular or an ovotesticular pattern may represent different degrees of the same process, because ovotestis and testicular types may co-exist in the same animal. Moreover, the centre-to-pole temporal profile in the differentiation of Sertoli cells [44] may contribute to imbalances in the propagation of the differentiation wave, allowing the two types of arrangement to develop. Meyers-Wallen proposed that, at least in the familiar American Cocker DSD syndrome, the phenotypic variability is probably related to threshold effects [8].

In the case of canine SRY-negative DSD, the mechanism responsible for the presence of testicular tissue remains unclear. Species-specific differences resulting from the process and the time-lapse of the gonad differentiation might be responsible for the divergence of phenotypes described in XX;SRY-negative sex reversal, both amongst and within a species. It can also result from the disruption of distinct genetic pathways. Therefore, from this point on, this review will focus mainly on the studies regarding the etiopathogenesis of canine XX;SRY-negative conditions.

### **2.1.1 Loss of Function of NR5A1**

Mutation in the NR5A1 gene, causing loss of function [62], has been associated with primary ovarian insufficiency in women and with OT-DSD/T-DSD development in 46;XX individuals [41, 63]. It has been recently proposed that NR5A1 should be used to promote proliferation of gonadal somatic cells. The exact mechanism underlying this effect is not clear. Since NR5A1 coordinates the ability for steroidogenic synthesis, it is possible that this role in XX;SRY-negative DSD pathogenesis may not be only related with direct disruption of the ovary-specific pathways [64], but also to the control of cytochrome P450 steroid hydroxylase enzymes [65] and the ability to

create an estrogen-dominant environment, which has been shown to be determinant of an ovary-fate. In humans, loss of NR5A1 function is also accompanied by hypospadias, a condition also found in some cases of XX;SRY-negative dogs. Moreover, the persistence of Mullerian-derived structures, like the oviducts and the uterus, would also be supported by an impairment of the NR5A1 cascade, as this gene is a transcriptional regulator of the Anti-Mullerian Hormone [66], which secretion has been shown to be delayed in of XX;SRY-negative dogs [8]. However, the few genetic and pedigree studies developed in XX;SRY-negative DSD in dogs considered NR5A1 unlikely to be a causative gene for this condition in the species [8, 66].

### 2.2.2 Loss of Function of Wnt4/Rspon1/ $\beta$ -Catenin and Foxl2 Pathways

On respect to WNT4 and RSPO1 loss-of-function, a premature differentiation of granulosa cells will occur, and the subsequent transdifferentiation of these cells and impaired oogonial differentiation or entering meiosis [47]. Any malfunctioning on the Wnt4/Rspon1/ $\beta$ -Catenin pathway would reflect in a failure to downregulate SOX9 transcription, thus potentially supporting the differentiation of a male-like gonad. In addition, since Wnt also supports Follistatin expression, a loss of function of WNT4 transcription would also explain the reduced number of follicles and oocytes found in the ovotestis sub-type DSD. Besides, as such loss of function would also enhance testosterone synthesis, the increased secretion of androgens could explain the partial masculinization of genital ducts, and the development of epididymides and deferens ducts in XX;SRY-negative individuals [67]. Studies on the methylation of WNT4 gene showed that methylation was similar in XX DSD and control dogs [30], suggesting that this may not be an adequate candidate gene for the XX DSD syndrome in dogs. Still, a decreased transcription of WNT4 was reported in XX DSD embryos using a genome wide association study and whole genome sequencing [13]. The same study describes a decrease in RSPO1 and FOXL2 expression, demonstrating that the ovary determining genes are downregulated in canine gonads from embryos at risk of XX DSD, while the testicular determining genes (namely the SOX9 and FGF9) are up-regulated [13].

Even though the participation of FOXL2 reported in the pathogen of sex reversal conditions in some species, like the goat, supported its study as a candidate gene for canine ovotesticular DSD, it has been demonstrated that FOXL2 is not responsible for the canine disorder [1, 66]. A similar conclusion was drawn regarding the participation of the  $\beta$ -catenin gene [1].

### 2.2.3 Gain of Function of SOX9

Expression of SOX9 was found to be increased in the absence of SRY, thanks to the participation of different activators [49]. A SOX9 enhancer was identified upstream of the SOX9 transcription start site, which is a target to steroidogenic factor 1 (SF1) and SRY [68]. As these enhancers usually participate in an autoregulatory loop, they sustain each other's expression through time. Mutations of this enhancer may be responsible for abolishing the need for SRY activation and consequently to the gain of function of the SOX9 signaling cascade.

Albeit a duplication of the SOX9 coding region has been found in two dogs diagnosed as XX;SRY-negative [69], some studies demonstrated that other individuals do not present SOX9 duplication [21, 70]. Conversely, duplication [15] or copy variations [13] of a region upstream of the SOX9 gene have been identified in XX;SRY-negative dogs. Two highly polymorphic copy

number variable regions have been identified in upstream regions to the canine SOX9 gene; one of those being at a similar distance from the SOX9 as that of the human RevSex [29]. One of these regions likely contains an enhancer region for SOX9 [13, 70], whose duplication may induce the SOX9 expression in the absence of SRY [29].

Recently, significantly higher methylation of SOX3 gene [30] has been reported in both the ovotesticular and the testicular canine XX DSD. In mice, it has been shown that SOX3 can replace SRY and drive the differentiating gonad towards a female fate [63].

### **3. Final Considerations**

Despite all of the progress made through the years on the elimination of canine XX;SRY-negative candidate genes, the molecular mechanisms involved in the etiopathogenesis of canine XX DSD remain poorly characterized. The mechanisms orchestrating the ovary-to-testicular or ovotesticular reversal in the absence of SRY remain elusive, not only in dogs but also in other species. The existence of a wide variety of phenotypes only adds to the difficulties in finding an explanation. For that, the histopathological examination of the gonads of animals with DSD is very important and supplementary to cytogenetic tests. Albeit a large number of reports exist in canine sex reversal, some descriptions of the clinical conditions are not supported by adequate karyotyping and cytogenetic analyses, thus representing pure diagnostic speculations. Also, it would be important to obtain sex hormone profiles from animals suffering from this condition to support clinical findings, in particular in respect to the production of androgens and the ability to convert testosterone to dihydrotestosterone. Recent studies focus now on the up-regulation of SOX9 transcription in the absence of SRY, in particular on the gain-of-function of SOX9 enhancer regions, as well as on the eventual participation of other SOX genes, e.g. the SOX3. The use of larger cohorts of individuals, either purebreds, mongrels or crosses, would be helpful to validate the participation of those candidate genes and to confirm the genetic transmission of the disease.

### **Acknowledgments**

Prof. Marek Switonski and his team are acknowledged for performing the karyotype and cytogenetic analysis in the cases used to produce Figures 1–5. Similarly, Prof. Maria dos Anjos Pires is acknowledged for her involvement in the histopathological evaluation of excised surgical specimens used in Figures 1–3.

### **Author Contributions**

RP-C ensured the conception and design of this review; using her clinical case load as a starting point she retrieved the necessary literature sources to support her evidences and discuss the topic of this review. She drafted the manuscript and performed the critical revision of the article.

### **Funding**

This work is funded by National Funds through FCT-Foundation for Science and Technology under the Project UID/AGR/00115/2019.



## Competing Interests

The author has declared that no competing interests exist.


## References

1. Salamon S, Nowacka-Woszuik J, Switonski M. Polymorphism of the CTNNB1 and FOXL2 genes is not associated with canine XX testicular/ovotesticular disorder of sex development. *Folia Biol.* 2015; 63: 57-62.
2. Parma P, Veyrunes F, Pailhoux E. Sex reversal in non-human placental mammals. *Sex Dev.* 2016; 10: 326-344.
3. Villagómez DAF, Lear TL, Chenier T, Lee S, McGee RB, Cahill J, et al. Equine disorders of sexual development in 17 mares including XX, SRY-negative, XY,SRY-negative and XY,SRY-positive genotypes. *Sex Dev.* 2011; 5: 16-25.
4. Torres A, Silva J, Bernardes N, Sales Luís J, Lopes da Costa L. 64, XX, SRY-negative, Testicular DSD syndrome in a lusitano horse. *Reprod Domest Anim.* 2013; 48: e33-e37.
5. De Lorenzi L, Banco B, Previderè C, Bonacina S, Romagnoli S, Grieco V, et al. Testicular XX (SRY-negative) disorder of sex development in cat. *Sex Dev.* 2017; 11: 210-216.
6. Switoński M, Jackowiak H, Godynicki S, Klukowska J, Borsiak K, Urbaniak K. Familial occurrence of pig intersexes (38,XX;SRY-negative) on a commercial fattening farm. *Anim Reprod Sci.* 2002; 69: 117-124.
7. Poth T, Breuer W, Walter B, Hecht W, Hermanns W. Disorders of sex development in the dog- Adoption of a new nomenclature and reclassification of reported cases. *Anim Reprod Sci.* 2010; 121: 197-207.
8. Meyers-Wallen VN. Gonadal and sex differentiation abnormalities of dogs and cats. *Sex Dev.* 2012; 6: 46-60.
9. Switonski M, Payan-Carreira R, Bartz M, Nowacka-Woszuik J, Szczerbal I, Colaço B, et al. Hypospadias in a male (78,XY; SRY-positive) dog and sex reversal female (78,XX;SRY-negative) dogs: clinical, histological and genetic studies. *Sex Dev.* 2012; 6: 128-134.
10. Selden JR, Wachtel SS, Koo GC, Haskins ME, Patterson DF. Genetic basis of XX male syndrome and XX true hermaphroditism: evidence in the dog. *Science.* 1978; 201: 644-646.
11. Meyers-Wallen VN. Review and update: genomic and molecular advances in sex determination and differentiation in small animals. *Reprod Domest Anim.* 2009; 44: 40-46.
12. Brennan J, Capel B. One tissue, two fates: molecular genetic events that underlie testis versus ovary development. *Nat Rev Genet.* 2004; 5: 509-521.
13. Meyers-Wallen VN, Boyko AR, Danko CG, Grenier JK, Mezey JG, Hayward JJ, et al. XX disorder of sex development is associated with an insertion on chromosome 9 and downregulation of RSPO1 in dogs (*canis lupus familiaris*). *PLoS One.* 2017; 12: e0186331.
14. Christensen BW. Disorders of sexual development in dogs and cats. *Vet Clin North Am Small Anim Pract.* 2012; 42: 515-526.
15. Szczerbal I, Nowacka-Woszuik J, Dzimira S, Atamaniuk W, Nizanski W, Switonski M. A rare case of testicular disorder of sex development in a dog (78, XX;SRY-negative) with male external genitalia and detection of copy number variation in the region upstream of the SOX9 gene. *sexual development.* 2016; 10: 74-78.

16. Rota A, Cucuzza AS, Iussich S, DeLorenzi L, Parma P. The case of an SRY-negative XX male pug with an inguinal gonad. *Reprod Domest Anim.* 2010; 45: 743-745.
17. Campos M, Moreno-Manzano V, García-Roselló M, García-Roselló E. SRY-negative XX sex reversal in a french bulldog. *Reprod Domest Anim.* 2011; 46: 185-188.
18. Kuiper H, Bunck C, Günzel-Apel AR, Drögemüller C, Hewicker-Trautwein M, Distl O. SRY-negative XX sex reversal in a Jack Russell Terrier: A case report. *Vet J.* 2005; 169: 116-117.
19. Nak D, Gulten T, Karkucak M, Yilmaz R, Nak Y, Simsek G, et al. SRY-negative XX sex reversal in an English Cocker Spaniel: A case report. *Vet Med.* 2015; 60: 170-173.
20. Pérez-Gutiérrez JF, Monteagudo LV, Rodríguez-Bertos A, García-Pérez E, Sánchez-Calabuig MJ, García-Botey C, et al. Bilateral ovotestes in a 78, XX *SRY*-negative beagle dog. *J Am Anim Hosp Assoc.* 2015; 51: 267-271.
21. Nowacka J, Nizanski W, Klimowicz M, Dzimira S, Switonski M. Lack of the SOX9 gene polymorphism in sex reversal dogs (78,XX;*SRY*-negative). *J Hered.* 2005; 96: 797-802.
22. Diel de Amorim M, Lerer A, Durzi T, Foster RA, Gartley CJ. Identification of ectopic ovotestis in a dog with XX ovotesticular, *SRY*-negative, disorder of sexual development. *Reprod Domest Anim.* 2018; 53: 822-825.
23. Gropetti D, Genuardo V, Bosi G, Pecile A, Iannuzzi A, Perucatti A, et al. XX *SRY*-Negative true hermaphroditism in two dogs: Clinical, morphological, genetic and cytogenetic studies. *Sex Dev.* 2012; 6: 135-142.
24. Melniczek JR, Dambach D, Prociuk U, Jezyk PF, Henthorn PS, Patterson DF, et al. *Sry*-negative XX sex reversal in a family of Norwegian Elkhounds. *J Vet Intern Med.* 1999; 13: 564-569.
25. Hubler M, Hauser B, Meyers-Wallen VN, Arnold S. *Sry*-negative XX true hermaphrodite in a Basset hound. *Theriogenology.* 1999; 51: 1391-1403.
26. Gurel A, Yildirim F, Sennazli G, Ozer K, Karabagli M, Deviren A, et al. Hermaphroditism in two dogs-pathological and cytogenetic studies: A case report. *Vet Med.* 2014; 59: 51-54.
27. Max A, Grabiec A, Sacharczuk M, Sysa P, Jurka P, Krzyzewska A. 78, XX testicular DSD syndrome in a mongrel dog. *Reprod Domest Anim.* 2012; 47: 7-11.
28. Meyers-Wallen VN, Schlafer D, Barr I, Lovell-Badge R, Keyzner A. *Sry*-negative XX sex reversal in purebred dogs. *Mol Reprod Dev.* 1999; 53: 266-273.
29. Nowacka-Wozzuk J, Szczerbal I, Pausch H, Hundi S, Hytönen MK, Grzemski A, et al. Deep sequencing of a candidate region harboring the SOX9 gene for the canine XX disorder of sex development. *Anim Genet.* 2017; 48: 330-337.
30. Salamon S, Flisikowski K, Switonski M. Methylation patterns of SOX3, SOX9, and WNT4 genes in gonads of dogs with XX (*SRY*-negative) disorder of sexual development. *Sex Dev.* 2017; 11: 86-93.
31. Payan-Carreira R, Pires MA, Nizanski W, Szczerbal I, Nowacka-Wozzuk J, Switonski M, editors. Gonadal morphology in sex reversal female dogs (78,XX;*SRY*-negative). 17th EVSSAR Congress; 2014; Wroclaw, Poland: EVSSAR.
32. Silversides DW, Benoit JM, Collard F, Gilson C. Disorder of sex development (XX male, *SRY* negative) in a French bulldog. *Can Vet J.* 2011; 52: 670-672.
33. Del Carro AP, Rosset E, Josson-Schramme A, Lambert V, Buff S. First description of scrotal testicles in a dog affected by 78,XX testicular disorder of sex development. *Reprod Domest Anim.* 2014; 49: E48-E52.

34. Svingen T, Koopman P. Building the mammalian testis: origins, differentiation, and assembly of the component cell populations. *Genes Dev.* 2013; 27: 2409-2426.
35. Morel Y, Roucher F, Mallet D, Plotton I. Genetic of gonadal determination. *Ann Endocrinol.* 2014; 75: 32-39.
36. Carlson BM. *Human embryology and developmental biology.* Philadelphia, USA: Elsevier, Mosby; 2004. p. 393-427.
37. Shnorhavorian M, Fechner PY. *Avery's diseases of the newborn.* 10th ed. Philadelphia: Elsevier; 2018. p. 1365-1387.
38. Koopman P. The curious world of gonadal development in mammals. *Curr Top Dev Biol.* 2016; 116: 537-545.
39. Koopman P, Wilhelm D. Insights into the aetiology of ovotesticular DSD from studies of mouse ovotestes. *Adv Exp Med Biol.* 2011; 707: 55-56.
40. Lin YT, Capel B. Cell fate commitment during mammalian sex determination. *Curr Opin Genet Dev.* 2015; 32: 144-152.
41. Bashamboo A, Eozenou C, Rojo S, McElreavey K. Anomalies in human sex determination provide unique insights into the complex genetic interactions of early gonad development. *Clin Genet.* 2017; 91: 143-156.
42. Larney C, Bailey TL, Koopman P. Switching on sex: transcriptional regulation of the testis-determining gene SRY. *Development.* 2014; 141: 2195-2205.
43. Romereim SM, Cupp AS. Mesonephric cell migration into the gonads and vascularization are processes crucial for testis development. *Results Probl Cell Differ.* 2016; 58: 67-100.
44. Greenfield A. Understanding sex determination in the mouse: genetics, epigenetics and the story of mutual antagonisms. *J Genet.* 2015; 94: 585-590.
45. Carré GA, Greenfield A. The gonadal supporting cell lineage and mammalian sex determination: the differentiation of sertoli and granulosa cells. *Results Probl Cell Differ.* 2016; 58: 47-66.
46. McClelland K, Bowles J, Koopman P. Male sex determination: Insights into molecular mechanisms. *Asian J Androl.* 2012; 14: 164-171.
47. Biason-Lauber A, Chaboissier MC. Ovarian development and disease: The known and the unexpected. *Semin Cell Dev Biol.* 2015; 45: 59-67.
48. Baetens D, Mendonça BB, Verdin H, Cools M, De Baere E. Non-coding variation in disorders of sex development. *Clin Genet.* 2017; 91: 163-172.
49. Capel B. Vertebrate sex determination: evolutionary plasticity of a fundamental switch. *Nat Rev Genet.* 2017; 18: 675-689.
50. Tevosian SG. Genetic control of ovarian development. *Sex Dev.* 2013; 7: 33-45.
51. Bowles J, Feng CW, Spiller C, Davidson TL, Jackson A, Koopman P. FGF9 suppresses meiosis and promotes male germ cell fate in mice. *Dev Cell.* 2010; 19: 440-449.
52. Brennan J, Karl J, Capel B. Divergent vascular mechanisms downstream of Sry establish the arterial system in the XY gonad. *Dev Bio.* 2002; 244: 418-428.
53. Wilhelm D, Palmer S, Koopman P. Sex determination and gonadal development in mammals. *Physiol Rev.* 2007; 87: 1-28.
54. Pannetier M, Pailhoux E. [Sex differentiation: state of the art and future prospects]. *Med Sci.* 2011; 27: 859-865.

55. Edson MA, Nagaraja AK, Matzuk MM. The mammalian ovary from genesis to revelation. *Endocr Rev.* 2009; 30: 624-712.
56. Suzuki H, Kanai-Azuma M, Kanai Y. From sex determination to initial folliculogenesis in mammalian ovaries: Morphogenetic waves along the anteroposterior and dorsoventral axes. *Sex Dev.* 2015; 9: 190-204.
57. Garcia-Ortiz JE, Pelosi E, Omari S, Nedorezov T, Piao Y, Karmazin J, et al. Foxl2 functions in sex determination and histogenesis throughout mouse ovary development. *BMC Dev Bio.* 2009; 9: 36.
58. Uhlenhaut NH, Jakob S, Anlag K, Eisenberger T, Sekido R, Kress J, et al. Somatic sex reprogramming of adult ovaries to testes by FOXL2 ablation. *Cell.* 2009; 139: 1130-1142.
59. Koubova J, Menke DB, Zhou Q, Capel B, Griswold MD, Page DC. Retinoic acid regulates sex-specific timing of meiotic initiation in mice. *Proc Natl Acad Sci USA.* 2006; 103: 2474-2479.
60. Pannetier M, Pailhoux E. [FOXL2, the gatekeeper of ovarian identity]. *Med Sci.* 2010; 26: 470-473.
61. Baillet A, Mandon-Pépin B, Veitia R, Cotinot C. [Genetics of early ovarian differentiation: recent data]. *Biol Aujourd'hui.* 2011; 205: 201-221.
62. Swartz JM, Ciarlo R, Guo MH, Abrha A, Weaver B, Diamond DA, et al. A 46, XX ovotesticular disorder of sex development likely caused by a steroidogenic factor-1 (NR5A1) variant. *Horm Res Paediatr.* 2017; 87: 191-195.
63. Bashamboo A, McElreavey K. Mechanism of Sex Determination in Humans: Insights from disorders of sex development. *Sex Dev.* 2016; 10: 313-325.
64. Bashamboo A, Donohoue PA, Vilain E, Rojo S, Calvel P, Seneviratne SN, et al. A recurrent p.Arg92Trp variant in steroidogenic factor-1 (NR5A1) can act as a molecular switch in human sex development. *Hum Mol Genet.* 2016; 25: 5286.
65. Lin L, Achermann JC. Steroidogenic factor-1 (SF-1, Ad4BP, NR5A1) and disorders of testis development. *Sex Dev.* 2008; 2: 200-209.
66. Kothapalli K, Kirkness E, Pujar S, Van Wormer R, Meyers-Wallen VN. Exclusion of candidate genes for canine SRY-negative XX sex reversal. *J Hered.* 2005; 96: 759-763.
67. Kobayashi K, Fujiwara T, Adachi T, Asahina M, Sasaki Y, Matsuda A, et al. Bilateral Ovotestes in a Female Beagle Dog. *J Toxicol Pathol.* 2007; 20: 111-115.
68. DiTacchio L, Bowles J, Shin S, Lim DS, Koopman P, Janknecht R. Transcription factors ER71/ETV2 and SOX9 participate in a positive feedback loop in fetal and adult mouse testis. *J Biol Chem.* 2012; 287: 23657-23666.
69. Rossi E, Radi O, De Lorenzi L, Vetro A, Groppetti D, Bigliardi E, et al. Sox9 duplications are a relevant cause of SRY-negative XX sex reversal dogs. *PLoS ONE.* 2014; 9: e101244.
70. Marcinkowska-Swojak M, Szczerbal I, Pausch H, Nowacka-Woszuik J, Flisikowski K, Dzimira S, et al. Copy number variation in the region harboring SOX9 gene in dogs with testicular/ovotesticular disorder of sex development (78,XX;SRY-negative). *Scientific Reports.* 2015; 5: 14696.



Enjoy *OBM Genetics* by:

1. [Submitting a manuscript](#)
2. [Joining in volunteer reviewer bank](#)
3. [Joining Editorial Board](#)
4. [Guest editing a special issue](#)

For more details, please visit:

<http://www.lidsen.com/journals/genetics>